



Contribution of dental private practitioners to publications on anatomical variations using cone beam computed tomography.

Authors:

Hebda A^{1,*} MS,

Theys S² DDS,

De Roissart J³ MD,

Perez E⁴ DDS,

Olszewski R^{1,3} DDS,MD,PhD,DrSc

Affiliations:

¹ Oral and maxillofacial surgery research Lab, NMSK, IREC, SSS, UCLouvain, Brussels, Belgium

² Department of pediatric dentistry and special care, Cliniques universitaires saint Luc, UCLouvain, Brussels, Belgium

³ Department of oral and maxillofacial surgery, Cliniques universitaires saint Luc, UCLouvain, Brussels, Belgium

⁴ Department of orthodontics, Cliniques universitaires saint Luc, UCLouvain, Brussels, Belgium

*Corresponding author: Hebda A, Oral and maxillofacial surgery research Lab, NMSK, IREC, SSS, UCLouvain, Brussels, Belgium, ORCID Id 0000-0001-5111-0021

23
24
25
26
27
28
29
30
31
32
33
34
35
36
37
38
39
40
41
42
43
44
45
46
47
48
49
50
51
52
53
54
55
56
57
58
59
60

Disclaimer: the views expressed in the submitted article are our own and not an official position of the institution or funder.

61

Abstract

62

63

64

65

66

67

68

69

70

71

72

73

74

75

76

77

78

79

80

81

82

83

84

85

86

87

88

89

90

91

92

93

94

95

96

97

98

99

Objective: To investigate the participation of citizens-dental private practitioner in scientific articles about anatomical variations on dentomaxillofacial CBCT. Our null hypothesis was that private practice practitioners are not involved in publications on anatomical variations using cone beam computed tomography.

Material and methods: This study was performed from home without access to our university library. Only PubMed database was used to perform our study. We found 384 articles published among 1830 articles corresponding to our inclusion/exclusion criteria. For each selected article we searched for affiliation of all of the authors (university, private dental practice, students, other). We applied a co-creation approach to involve colleagues from private practice in analyzing results of this study.

Results: A large majority of authors have university affiliation (96.5%). Only 3% of authors come from private practice. Most of articles belong to the group of 7 emergent economies (E7), and from Asia. 47.9% of 96 journals published only one article on anatomical variations discovered on CBCT. The higher number of articles (18.75%) were published by journals related to endodontics. The 84% of articles were dispersed among a vast span of general and specific dental, and maxillofacial journals. The 68.4% of articles on variations in CBCT were available in closed access and 31.6% of articles were available in open access. Only 6.7% of articles were published in open access without author publication charges (APC). The 31.6% of authors with university affiliation choose open access for their article. 7.8% of authors from private practice were involved in publishing in closed access journals and 2.34% in open access journals. Only 3 articles (0.78%) were published by authors affiliated to private practice without involvement of university authors. 2.6% of articles involved students as co-authors. Authors with other affiliation were involved only in one closed access publication. For the step of co-creation none of 183 private practitioners, and 3/33 (9%) university-affiliated members of Nemesis Facebook group actively participated in analyzing the results of this study.

Conclusions: the null hypothesis was accepted: dentists from private practice are exceptionally involved in publications on anatomical variations using CBCT in dentomaxillofacial area.

Keywords: cone beam computed tomography, CBCT, anatomical variation, citizen science, open access

100

101 **Introduction**

102 Citizen participative science is emerging part of open science practices. Open
 103 science means sharing as early as possible and not only between academics but with
 104 non-academics as well (<https://discovery.ucl.ac.uk/id/eprint/10058422/>). In medical
 105 research, participative science is not very popular. Patients are only considered as
 106 subject of the research, and sharing knowledge and data with patients is difficult
 107 because of the medical secret and of data protection. However, word "citizen" in
 108 citizen participative science refers to voluntary participation by nonprofessional
 109 contributors or professional contributors not involved in academic career. Building
 110 on our previous article on accessibility to the knowledge on anatomical variations
 111 from dentomaxillofacial cone beam computed tomography (CBCT) we found that
 112 articles on that topic with free open access represent an exception in dental literature
 113 [1]. Private practitioners were not able to quickly find pertinent reference figures on
 114 anatomical variation arising in dentomaxillofacial CBCT imaging [1]. The objective
 115 of our article was double: 1) to investigate the participation of citizens-dental private
 116 practitioner in scientific articles on anatomical variations on dentomaxillofacial
 117 CBCT, and 2) to involve citizens-private practice practitioners as well as their
 118 scholarly colleagues in analyzing results on the present study, and to evaluate the
 119 issues and limitations of this approach. Our null hypothesis was that private practice
 120 practitioners are not involved in publications on anatomical variations using cone
 121 beam computed tomography.

122 **Materials and methods**

123 The study was performed from home without access to our university library. We
 124 worked in the same experimental conditions as our private practice colleagues to
 125 access free scientific knowledge. We used some elements from systematic review
 126 methodology to find articles in a reproducible manner. The Scopus (institutional
 127 access only) and Embase (payment) databases were not used. Only PubMed
 128 database was used to perform our study. We wanted to search as many as possible
 129 articles on anatomic variations discovered and/or described in studies using CBCT.
 130 Our research equation for PubMed was set as follow:
 131 (CBCT[All Fields] AND ("anatomy and histology"[Subheading] OR ("anatomy"[All
 132 Fields] AND "histology"[All Fields]) OR "anatomy and histology"[All Fields] OR
 133 "anatomy"[All Fields] OR "anatomy"[MeSH Terms])) AND (hasabstract[text] AND
 134 "humans"[MeSH Terms] AND (English[lang] OR French[lang])). We accessed on
 135 PubMed on 24.07.2019.
 136 There was no time frame for our search (1948-2019). The languages selected were
 137 English and French. The inclusion criteria were set as follow: studies on CBCT on
 138 human anatomical variation in dentomaxillofacial area, studies with abstract.
 139 Clinical studies, case series and case reports were also selected.

140 The exclusion criteria were: experimental studies, in vitro studies, cadaver studies,
141 studies without information on anatomical variation in dentomaxillofacial CBCT
142 area, CBCT studies other than on dentomaxillofacial area, no author information, no
143 abstract.

144 One observer performed the search. The research equation provided with 1830
145 articles. Articles were then selected according to inclusion/exclusion criteria on
146 lecture of title and abstract. Articles were also excluded because of insufficient
147 information on author affiliation in PubMed database or on the journal webpage.
148 Finally, we found 384 articles [2-385].

149 For each selected article, we searched for affiliation of all of the authors. We needed
150 to search the information about author affiliation on the journal webpage when it
151 was not directly accessible from PubMed database. We subdivided affiliations onto:
152 1) University, 2) private practice, 3) student, 4) other occupation. Mixed affiliation
153 university and private practice was considered as university affiliation as the author
154 was able to use university access to his/her study. The student affiliation was
155 reserved for student before final graduation (not PhD students). We used the
156 category "other occupation" for radiological technicians.

157 We searched information about author's countries, and on journals publishing on
158 anatomical variations using CBCT. We wanted to know about the involvement of
159 different categories of authors in open access publication. We systematically
160 accessed to all journals webpages of all selected articles. We checked if the pdf file
161 was really accessible in open access journals. We searched for information on open
162 access type in instruction for authors which were of two types: with and without
163 author publication charges (APC).

164
165 The next step of methodology consisted of a co-creation approach to involve
166 colleagues from our and other university dental departments, and from private
167 practice in analyzing results and in writing conclusions.

168 A first draft of the article, composed of methodology and of 4 tables (Tables 1, 2,
169 13, and 14) with search results was published on the website of Nemesis. This was
170 formulated as an invitation to participate in the article and to write the analysis of
171 results. The Nemesis journal uses also social media – a group was created on
172 Facebook (in April 2020), where 228 members have subscribed. There were 183
173 private practitioners and 33 university affiliated members. The invitation and the
174 link to the draft was posted on Facebook (19 May 2020). One month deadline (until
175 19 June 2020) was set in to contribute to the article drafting. Potential participants
176 have been informed that this is an experimental approach and were given the
177 possibility to contact the editor-in-chief for any question.

178 After one month, all contributions have been collected by email and incorporated to
179 the new draft. All participants were given a new opportunity to comment through a
180 new invitation and link to the 2nd draft posted on Facebook. This time the
181 participants were also asked to give their feedback why they think that so little
182 private practice dentist are participating in scientific research and publication.

183

Results

184

185

186

187

188

189

190

191

192

193

194

195

196

From the Table 1 we can see that publication on CBCT anatomical variations started from 1999 onwards. Total number of articles on CBCT anatomical variations was multiplied by 7 comparing the same period of time before and after 2011. Total number of authors was multiplied by 20 comparing the same period of time before and after 2011. The number of authors/article tripled after 2011. A vast majority of authors have university affiliation (96.5%). Only 3% of authors come from private practice. Student involvement in publications is almost inexistent (0.5%). Between 2011-2019 appears a small but progressive lack of correct information on authors on Pubmed, and in the same period of time correct information on authors is achieved in scholarly journals.

Table 1. Information on included and excluded articles and on number and type of author's affiliation.

Years	Number of articles	Number of authors	Number of included articles	Number of excluded articles	Number of excluded articles with insufficient information	Number of authors with university affiliation	Number of private practice authors	Number of student authors	Number of other type of affiliations authors
2015-2019	800	1049	214	567	19	1002	40	7	0
2011-2015	800	737	152	620	28	720	13	4	0
1999-2011	230	84	18	210	2	80	3	0	1
1999-2019	TOTAL =1830	1870	384	1397	49	1802	56	12	1

197

198

199

200

201

202

203

204

205

206

207

208

209

210

211

212

213

The total number of articles from Tables 2-12 (n=475) is different from 402 articles from Tables 1, 13, and 14. Some articles were written together by colleagues from different countries, and counted separately for each country. United States and Turkey are the most publishing country on CBCT anatomical variations (Table 2). Most of articles come from the group of 7 emergent economies (E7) (Table 4), and from Asia (Table 10). Publications on CBCT variations in European Union (Table 5) with the longest scholarly traditions are below G7 (Table 3) and BRICS (Table 6) countries. The 8 of 10 European countries from ex-sovietic bloc have no published articles on CBCT variations in PubMed. Russia also has no oarticle on that topic. When we compare the continents, 44.7% of articles belong to Asia (Table 10), 25.3% to Europe (Tables 5, 7), 15.4% to North America (Table 8), and 12.1% to South America (Table 9). Africa (Table 11), and Oceania (Table 12) are deeply underrepresented (Fig. 1).

214
215**Table 2.** The total number of articles by authors countries. The list of countries is arranged alphabetically for the same number of articles.

Country of affiliated authors	The total number of articles
USA	67
Turkey	67
Brazil	49
China	38
India	31
South Korea	19
Spain	19
UK	17
Japan	16
Switzerland	16
Italy	15
Germany	11
Romania	11
Iran	8
Taiwan	8
Belgium	6
Portugal	6
Canada	5
France	5
Hong-Kong	5
Israel	5
Saudi Arabia	5
Australia	4
Egypt	4
Malaysia	4
Croatia	3
Greece	3
Poland	3
South Africa	3
Argentina	2
Chili	2
Syria	2
The Netherlands	2
Belarus	1
Costa Rica	1
Danmark	1
Finland	1
Georgia	1
Iceland	1
Iraq	1
Jamaica	1
Jordan	1
Mexico	1

Norway	1
Oman	1
Thailand	1
Venezuela	1
Total=47 countries	Total=475 articles

216
217
218

Table 3. The total number of articles by countries belonging to G7 (major developed countries).

Country	The total number of articles
USA	67
UK	17
Japan	16
Italy	15
Germany	11
France	5
Canada	5
Total= 7	Total=136

219
220
221

Table 4. The total number of articles by countries belonging to E7 (emerging economy countries).

Country	The total number of articles
Turkey	67
Brazil	49
China	38
India	31
Mexico	1
Indonesia	0
Russia	0
Total=7	Total=186

222
223
224

Table 5. The total number of articles by countries belonging to European Union.

Country	The total number of articles
Spain	19
Italy	15
Germany	11
Romania	11
Belgium	6
Portugal	6
France	5
Croatia	3
Greece	3
Poland	3
The Netherlands	2
Denmark	1
Finland	1
Austria	0

Bulgaria	0
Cyprus	0
Estonia	0
Hungary	0
Ireland	0
Latvia	0
Lithuania	0
Luxembourg	0
Malta	0
Czechia	0
Slovakia	0
Slovenia	0
Sweden	0
Total= 27	Total=86

225
226
227

Table 6. The total number of articles by countries belonging to BRICS countries.

Country	The total number of articles
Brazil	49
China	38
India	31
South Africa	3
Russia	0
Total=5	Total=121

228
229
230

Table 7. The total number of articles by countries belonging to European countries other than European Union.

Country	The total number of articles
UK	17
Switzerland	16
Belarus	1
Iceland	1
Norway	1
Total=5	Total=36

231
232

Table 8. The total number of articles by countries in North America.

Country	The total number of articles
USA	67
Canada	5
Mexico	1
Total=3	Total=73

233
234
235

Table 9. The total number of articles by countries in South America.

Country	The total number of articles
Brazil	49
Argentina	2

Chili	2
Costa Rica	1
Jamaica	1
Venezuela	1
Total=6	Total=56

236
237

Table 10. The total number of articles by countries in Asia.

Country	The total number of articles
Turkey	67
China	38
India	31
South Korea	19
Japan	16
Iran	8
Taiwan	8
Hong-Kong	5
Israel	5
Saudi Arabia	5
Malaysia	4
Syria	2
Georgia	1
Iraq	1
Jordan	1
Thailand	1
Oman	1
Total=17	Total=213

238
239

Table 11. The total number of articles by countries in Africa.

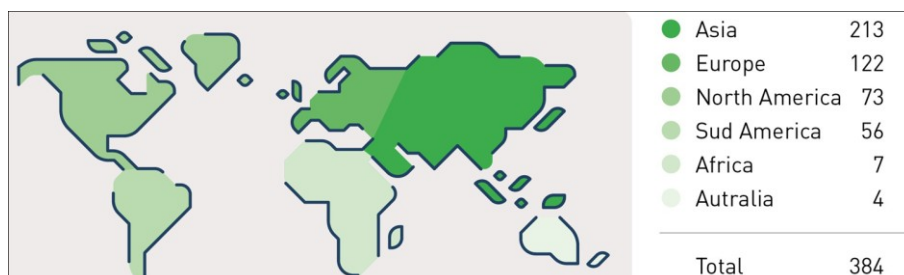Country	The total number of articles
Egypt	4
South Africa	3
Total= 2	Total=7

240
241

Table 12. The total number of articles by countries in Oceania.

Country	The total number of articles
Australia	4

242
243
244
245
246
247
248
249
250
251

252
253**Fig. 1.** The total number of articles by continents.254
255
256
257
258
259
260
261
262
263
264

The 46 of 96 journals (47.9%) published only one article on anatomical variations discovered on CBCT (Table 13). The higher number of articles (18.75%) were published by journals related to endodontics. Journal with the scope of dentomaxillofacial radiology accepted only 15.36% of all articles on anatomical variations on CBCT. Therefore, 84% of articles were dispersed among a large span of general and specific dental, and maxillofacial journals.

Table 13. The total number of articles by journal titles. The list of journals is arranged alphabetically for the same number of articles.

Journal Title	The total number of articles
J Endod	54
Surg Radiol Anat	42
Int Endod J	17
J Craniofac Surg	13
Oral Surg Oral Med Oral Pathol Oral Radiol	13
Clin Oral Investig	11
Clin Implant Dent Relat Res	10
Dentomaxillofac Radiol	10
Implant Dent	9
J Contemp Dent Pract	8
Int J Oral Maxillofac Surg	7
Rom J Morphol Embryol	7
Acta Odontol Scand	6
Am J Orthod Dentofacial Orthop	6
Braz Dent J	6
Braz Oral Res	6
Head Face Med	5
Indian J Dent Res	5
J Oral Maxillofac Surg	5
Niger J Clin Pract	5
PLoS One	5
Ann Anat	4
Arch Oral Biol	4

Clin Oral Implant Res	4
Eur J Orthod	4
Forensic Sci Int	4
J Forensic Sci	4
J Formos Med Assoc	4
Med Oral Patol Oral Cir Bucal	4
Minerva Stomatol	4
Oral Maxillofac Surg	4
Angle Orthod	3
Biomed Res Int	3
BMC Med Imaging	3
Br J Oral Maxillofac Surg	3
Dent Clin North Am	3
Eur Arch Otorhinolaryngol	3
Int J Oral Sci	3
J Appl Oral Sci	3
J Craniomaxillofac Surg	3
J Oral Implantol	3
Acta Odontol Latinoam	2
Aust Dent J	2
BMC Oral Health	2
Clin Anat	2
J Forensic Leg Med	2
J Investig Clin Dent	2
J Oral Rehabil	2
Med Princ Pract	2
Sci Rep	2
Acta Med Acad	1
Acta Radiol	1
Anat Sci Int	1
Aust Endod J	1
Br Dent J	1
Bull Tokyo Dent Coll	1
Clin Imaging	1
Compend Contin Educ Dent	1
Cranio	1
Dental Press J Orthod	1
Dent Traumatol	1
Diagn Interv Radiol	1
Eur Rev Med Pharmacol Sci	1
Folia Morphol (Warsz)	1
Georgian Med News	1
Ger Med Sci	1
In Vivo	1
Int Dent J	1
Int J Artif Organs	1
Int J Legal Med	1
Int J Pediatr Otorhinolaryngol	1

J Am Dent Assoc	1
J Anat	1
J Clin Periodontol	1
J Coll Physicians Surg Pak	1
J Dent Child (Chic)	1
J Indian Soc Pedod Prev Dent	1
J Oral Sci	1
J Orthod	1
J Prosthet Dent	1
J Prosthodont	1
J Zhejiang Univ Sci B	1
Leg Med (Tokyo)	1
Med Sci Monit	1
Microsc Res Tech	1
Morphologie	1
Mymensingh Med J	1
Odontology	1
Okajimas Folia Anat Jpn	1
Oral Dis	1
Orthod Craniofac Res	1
Prog Orthod	1
Radiol Med	1
Rev Stomatol Chir Maxillofac	1
Saudi Med J	1
Sultan Qaboos Univ Med J	1
Total= 96 journals	Total=384 articles

265
266
267
268
269
270
271
272
273
274
275
276
277
278
279
280
281
282
283
284

The 68.4% of articles on variations in CBCT were available in closed access, and 31.6% of articles were available in open access (Table 14). However, only 6.7% of articles were published in open access without author publication charges (APC). The 31.6% of authors with university affiliation choose open access for their article. The 24.7% of authors with university affiliation published in journals with open access and APC. The 6.7% of authors with university affiliation published in journals with open access and without APC. The 7.8% of authors from private practice were involved in publishing in closed access journals and 2.34% in open access journals. Only 3 articles (0.78%) were published by authors affiliated to private practice without involvement of university authors. Students were involved as co-authors in 2.6% of articles. Authors with other affiliation were involved only in one closed access publication (Fig. 2.).

285

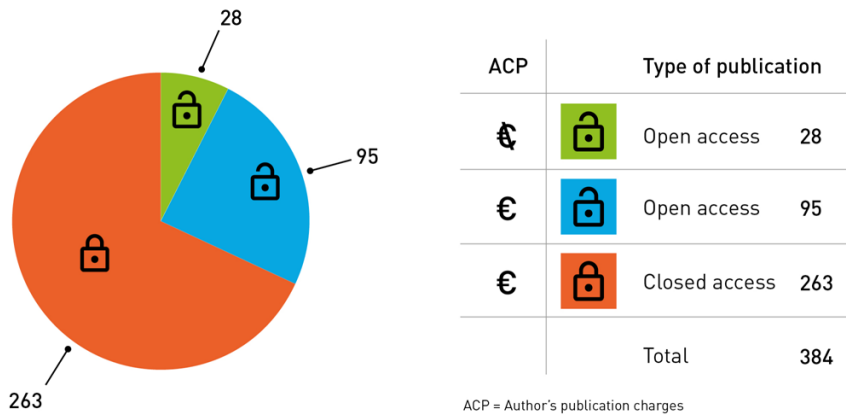
Table 14. Open and closed access publication type for selected articles.

	CA + UNI	CA + UNI + Priv	CA + UNI + Student	CA + Priv	CA + UNI + Tech	OA + APC+ UNI	OA + APC + UNI + Priv	OA + APC + UNI + Student	OA with NO APC + UNI	OA with NO APC + UNI + Priv
Total= 384 articles	226	27	6	3	1	84	7	4	24	2

286
287
288
289
290
291
292

CA: closed access, OP: open access, APC: author publication charges, UNI: author university affiliation, Priv: author private practice affiliation, Student: author is a student from a given university, Tech: author is a technician affiliated to University clinic.

Fig. 2. The total number of articles related to the type of access, and presence or absence of author publication charges.



293
294
295
296
297
298
299

For the step of co-creation only 3 of 33 (9%) university affiliated members of Nemesis Facebook group answered after the first call, and one university affiliated member answered again after the second call. There was no involvement of any of 183 private practitioners from Nemesis Facebook group.

300

Discussion

301
302
303
304
305

The interest in describing human anatomical variation discovered on CBCT is increasing in scholarly literature (Table 1). However, the role of private practitioner in its development is not significant (Table 1). Various hypotheses can be put forward to explain the low participation of private practitioners without university affiliation in scientific publications on anatomical variations on CBCT. The research

306 itself and the science community may be difficult to access and seems to be reserved
307 to a kind of elite. Scientific literature is not easily accessible as the majority of
308 articles are accessible under closed access-paywalls (Table 14, Fig. 2). There exists a
309 real difficulty for private practitioner to produce a publication with sufficient quality
310 required by scholarly journals, and without any collaboration with scholarly experts
311 (methodology aspects, scientific writing, publication process). The private
312 practitioner may also feel overwhelmed by the large number of scientific
313 publications and thus not feel up to date or not feel able to make an original
314 contribution. The private practitioner may lack training in analyzing the whole
315 CBCT field of view, and remain focused only on their area of interest. They may
316 therefore not observe the anatomical variations. There may be a lack of details in
317 received protocols as they only answer to question asked by practitioners. The latter
318 is not aware of the existence of anatomical variations. Another difficulty may come
319 from access to the CBCT device which is more difficult in private practice than in
320 hospitals and/or university clinics even if this tends to improve in recent years.
321 Quantity of articles related to anatomical variations on CBCT is in relation with the
322 economic power of given country, geographic area, or economic club (Tables 2-12).
323 Articles are written in areas where there is an easy access to CBCT technology.
324 CBCT is still expansive in comparison with conventional dental radiography. It
325 needs the national implementation of special laws for patients radioprotection, and
326 its safe and justified use by the dental practitioner. There is also a major need of
327 post-university education for dentists, and maxillofacial surgeons using CBCT on
328 daily basis, as CBCT was only introduced in dental practice from 2003. CBCT is
329 also used for advanced dentistry (endodontics, implantology) which can be
330 performed only in economically stable countries due to higher costs.
331 Prevalence and type of anatomical variations seen on CBCT are different for
332 different human populations [3, 13-15, 22, 23, 26, 35, 38, 64, 69, 79, 84, 88, 94, 99,
333 103, 106, 128, 131, 150, 151, 153, 162, 170, 174, 177, 178, 181, 197, 202, 209, 212,
334 217, 226, 229, 230, 232, 241, 244, 245, 253, 255, 270, 279, 282, 288, 293, 297, 303,
335 308, 313, 323, 325, 327, 343, 346, 349, 358, 360, 364, 370, 378]. Some populations
336 are currently better described than other (55.4% of articles from Asia vs 31.7% from
337 Europe). Anatomical variations on dentomaxillofacial CBCT still wait to be
338 discovered on continents such as Africa and Oceania.
339 There is no real recognized leader journal which may accept the majority of articles
340 related to anatomic variations discovered on CBCT (Table 13). Such articles may be
341 single case reports that are known to be further less cited. Therefore, they will not be
342 or be scarcely accepted by Editors as they do not contribute to increase the impact
343 factor of a given journal.
344 In present situation a great majority of scholarly authors have no chance to access to
345 all of these journals through their university library, as they library should subscribe
346 to all of the titles from Table 13. Private practitioners have no chance at all to
347 quickly access to the information they need immediately when they are confronted
348 with a specific CBCT case in their own practice.

349 Variation of root canals in CBCT seems to be an overrepresented topic. From the
350 other hand, one article on a selected topic cannot itself embrace all the complexity of
351 a given type of CBCT variation.

352 Open access is an option more and more selected by university affiliation authors
353 (Table 14, Fig. 2). It seems not known by authors from private practice. However,
354 closed access to articles on CBCT anatomical variations is still the most prevalent.
355 This situation limits the advancement of research on human CBCT variations in
356 dentomaxillofacial area by scholarly authors with limited budget. Moreover, dentists
357 from private practice have no guarantee to find any reference figure to immediately
358 compare with their clinical case in the paid (closed access) article. Dental journals
359 without APC are very rare [1], and therefore articles with open access without APC
360 are still the rarest type of publication.

361 In our study, we decided to involve citizens, which are private practice dentists not
362 involved in any academic career. The incentive for active participation in our
363 research was to become co-author of the final version of the article. We also granted
364 the personalized contact with the Editor-in-Chief to overcome shyness of private
365 practitioners. However, none of 183 private practitioners answered to our two calls
366 through the Nemesis website, and through Facebook Nemesis group. We may
367 explain our failure by the fact that we asked not-research trained colleagues to
368 review a specific type of scholarly methodology using only a social media which is
369 mostly used for personal entertainment. We should rather try to organize a workshop
370 to clarify our expectations in face-to-face manner with our colleagues from private
371 practice. This approach was impossible this time due to Covid-19 situation in
372 Belgium.

373 The main limitation was the use of only one PubMed database, which was free of
374 use from home. Directory of Open access journals (DOAJ) was not selected. DOAJ
375 is a database which excludes closed access articles in any given topic, and therefore
376 which hidden the major issue of pay-walls in science. Barrier of language may also
377 be a bias in our study as only articles in English and French were selected. Russia is
378 an example of developed country with recognized scientific tradition, and with
379 missing data for our research. Russian authors may publish in their own language
380 and in journals not selected in PubMed database.

381 Finally, the null hypothesis was accepted: dentists from private practice are rarely
382 involved in publications on anatomical variations using CBCT in dentomaxillofacial
383 area.

384

385

- 386 • **Acknowledgements:** We would like to thank Mrs MH Grégoire, Presses
 387 universitaires de Louvain (PUL), UCLouvain, Belgium, for figures preparation.
 388 • **Funding sources statement:** this study does not received any funding.
 389 • **Competing interests:** Prof R. Olszewski declares competing interests as Editor-
 390 in-Chief of Nemesis. All other authors declare no conflicts of interest.
 391 • **Ethical approval:** There was no need for ethical committee approval for this
 392 study.
 393 • **Informed consent:** There was no need for informed consent for this study.

394

Authors contribution:

Author	Contributor role
Hebda Aleksandra	Conceptualization, Methodology, Resources, Validation, Writing original draft preparation, Supervision, Writing review and editing
Theys Stéphanie	Validation, Writing original draft preparation, Writing review and editing
De Roissart Jean	Validation, Writing original draft preparation, Writing review and editing
Perez Eytan	Validation, Writing original draft preparation, Writing review and editing
Olszewski Raphael	Conceptualization, Data curation, Investigation, Methodology, Resources, Validation, Writing original draft preparation, Supervision, Writing review and editing

395

396

References

- 397 1. Olszewski R. Hebda A. Accessibility to the knowledge on anatomical variations
 398 from dentomaxillofacial CBCT. Nemesis 2020;10:1-19.
 399 DOI: <https://doi.org/10.14428/nemesis.v10i1.53063>

400
401
402
403
404
405
406
407
408
409
410
411
412
413
414
415
416
417
418
419
420
421
422
423
424
425
426
427
428
429
430
431
432
433
434
435
436
437
438
439
440
441
442

2. Duruel O, Kulkarni V, Ataman-Duruel ET, Tözüm MD, Tözüm TF. Radio-Morphometric evaluation of greater palatine canal and pterygopalatine fossa component: maxillary anesthetic implications. *J Craniofac Surg* 2019;30:863-867.
3. Aytugar E, Özeren C, Lacin N, Veli I, Çene E. Cone-beam computed tomographic evaluation of accessory mental foramen in a Turkish population. *Anat Sci Int* 2019;94:257-265.
4. Bahşi İ, Orhan M, Kervancioğlu P, Yalçın ED. The anatomical and radiological evaluation of the Vidian canal on cone-beam computed tomography images. *Eur Arch Otorhinolaryngol* 2019;276:1373-1383.
5. Icen M, Orhan K. Cone-beam computed tomography evaluation of the pterygomaxillary fissure and pterygopalatine fossa using 3D rendering programs. *Surg Radiol Anat* 2019;41:513-522.
6. Bayrak S, Göller Bulut D, Orhan K. Prevalence of anatomical variants in the clivus: fossa navicularis magna, canalis basilaris medianus, and craniopharyngeal canal. *Surg Radiol Anat* 2019;41:477-483.
7. Ling C, Jiang Q, Ding X. Cone-Beam computed tomography study on morphologic characteristics of the posterior region in hard palate. *J Craniofac Surg* 2019;30:921-925.
8. Ottersen MK, Abrahamsson AK, Larheim TA, Arvidsson LZ. CBCT characteristics and interpretation challenges of temporomandibular joint osteoarthritis in a hand osteoarthritis cohort. *Dentomaxillofac Radiol* 2019;48:20180245.
9. Kapoor V, Kumar N, Dahiya K, Sikka R, Sirana P, Singh A. To assess and evaluate the variation of mandibular anatomy using cone beam computed tomography before planning an implant surgery: a population-based retrospective study. *J Contemp Dent Pract* 2018;19:1381-1385.
10. Rajput BS, Merita S, Parihar AS, Vyas T, Kaur P, Chansoria S. Assessment of lingual concavities in submandibular fossa region in patients requiring dental implants-A cone beam computed tomography study. *J Contemp Dent Pract* 2018;19:1329-1333.
11. Rusu MC, Măru N, Sava CJ, Săndulescu M, Dincă D. Rare anatomic variation: Giant unilateral concha bullosa superior. *Morphologie* 2019;103:54-59.

- 443 12. Şimşek Kaya G, Daltaban Ö, Kaya M, Kocabalkan B, Sindel A, Akdağ M. The
444 potential clinical relevance of anatomical structures and variations of the maxillary
445 sinus for planned sinus floor elevation procedures: A retrospective cone beam
446 computed tomography study. *Clin Implant Dent Relat Res* 2019;21:114-121.
447
- 448 13. Corbella S, Baruffaldi M, Perondi I, Taschieri S. Cone-beam computed
449 tomography investigation of the anatomy of permanent mandibular premolars in a
450 cohort of Caucasians. *J Investig Clin Dent* 2019;10:e12373.
451
- 452 14. Su CC, Huang RY, Wu YC, Cheng WC, Chiang HS, Chung MP, Cathy Tsai
453 YW, Chung CH, Shieh YS. Detection and location of second mesiobuccal canal in
454 permanent maxillary teeth: A cone-beam computed tomography analysis in a
455 Taiwanese population. *Arch Oral Biol* 2019;98:108-114.
456
- 457 15. Rodricks D, Phulambrikar T, Singh SK, Gupta A. Evaluation of incidence of
458 mental nerve loop in Central India population using cone beam computed
459 tomography. *Indian J Dent Res* 2018;29:627-633.
460
- 461 16. Polo CL, Abdelkarim AZ, von Arx T, Lozanoff S. The morphology of the
462 infraorbital nerve and foramen in the presence of an accessory infraorbital foramen.
463 *J Craniofac Surg* 2019;30:244-253.
464
- 465 17. Aps JKM, Gazdeck LY, Nelson T, Slayton RL, Scott JM. Assessment of the
466 location of the mandibular lingula in pediatric patients using cone beam computed
467 tomography images. *J Dent Child (Chic)* 2018;85:58-65.
468
- 469 18. Aksoy U, Orhan K. Risk factor in endodontic treatment: topographic evaluation
470 of mandibular posterior teeth and lingual cortical plate using cone beam computed
471 tomography (CT). *Med Sci Monit* 2018;24:7508-7516.
472
- 473 19. Fontolliet M, Bornstein MM, von Arx T. Characteristics and dimensions of the
474 infraorbital canal: a radiographic analysis using cone beam computed tomography
475 (CBCT). *Surg Radiol Anat* 2019;41:169-179.
476
- 477 20. Estrela C, Couto GS, Bueno MR, Bueno KG, Estrela LRA, Porto OCL,
478 Diogenes A. Apical foramen position in relation to proximal root surfaces of human
479 permanent teeth determined by using a new cone-beam computed tomographic
480 software. *J Endod* 2018;44:1741-1748.
481
- 482 21. Martins JNR, Alkhawas MAM, Altaki Z, Bellardini G, Berti L, Boveda C,
483 Chaniotis A, Flynn D, Gonzalez JA, Kottoor J, Marques MS, Monroe A, Ounsi HF,
484 Parashos P, Plotino G, Ragnarsson MF, Aguilar RR, Santiago F, Seedat HC, Vargas
485 W, von Zuben M, Zhang Y, Gu Y, Ginjeira A. Worldwide analyses of maxillary

- 486 first molar second mesiobuccal prevalence: a multicenter cone-beam computed
487 tomographic study. *J Endod* 2018;44:1641-1649.
488
- 489 22. Saber SEDM, Ahmed MHM, Obeid M, Ahmed HMA. Root and canal
490 morphology of maxillary premolar teeth in an Egyptian subpopulation using two
491 classification systems: a cone beam computed tomography study. *Int Endod J*
492 2019;52:267-278.
493
- 494 23. Alqedairi A, Alfawaz H, Al-Dahman Y, Alnassar F, Al-Jebaly A, Alsubait S.
495 Cone-Beam computed tomographic evaluation of root canal morphology of
496 maxillary premolars in a Saudi population. *Biomed Res Int* 2018;2018:8170620.
497
- 498 24. Ataman-Duruel ET, Duruel O, Turkyilmaz I, Tözüm TF. Anatomic variation of
499 posterior superior alveolar artery: review of literature and case introduction. *J Oral*
500 *Implantol* 2019;45:79-85.
501
- 502 25. Rocha BCS, Andrade J, Valerio CS, Manzi FR. Enamel pearl diagnosed by cone
503 beam computed tomography: A clinical case report. *Indian J Dent Res* 2018;29:517-
504 520.
505
- 506 26. Kavarthapu A, Thamaraiselvan M. Assessing the variation in course and position
507 of inferior alveolar nerve among south Indian population: A cone beam computed
508 tomographic study. *Indian J Dent Res* 2018;29:405-409.
509
- 510 27. Vieira CL, Veloso SDAR, Lopes FF. Location of the course of the mandibular
511 canal, anterior loop and accessory mental foramen through cone-beam computed
512 tomography. *Surg Radiol Anat* 2018;40:1411-1417.
513
- 514 28. Yurdabakan ZZ, Okumus O, Pekiner FN. Evaluation of the maxillary third
515 molars and maxillary sinus using cone-beam computed tomography. *Niger J Clin*
516 *Pract* 2018;21:1050-1058.
517
- 518 29. Demiralp KÖ, Kurşun-Çakmak EŞ, Bayrak S, Sahin O, Atakan C, Orhan K.
519 Evaluation of anatomical and volumetric characteristics of the nasopalatine canal in
520 anterior dentate and edentulous individuals: a CBCT study. *Implant Dent*
521 2018;27:474-479.
522
- 523 30. Başı I, Orhan M, Kervancıoğlu P, Yalçın ED, Aktan AM. Anatomical
524 evaluation of nasopalatine canal on cone beam computed tomography images. *Folia*
525 *Morphol (Warsz)* 2019;78:153-162.
526
- 527 31. Li YH, Bao SJ, Yang XW, Tian XM, Wei B, Zheng YL. Symmetry of root
528 anatomy and root canal morphology in maxillary premolars analyzed using cone-
529 beam computed tomography. *Arch Oral Biol* 2018;94:84-92.

- 530
531 32. Saati S, Shokri A, Foroozandeh M, Poorolajal J, Mosleh N. Root morphology
532 and number of canals in mandibular central and lateral incisors using cone beam
533 computed tomography. *Braz Dent J* 2018;29:239-244.
534
- 535 33. Ayach OA, Hadad R. Correlation between cervical vertebrae volume
536 parameter and the skeletal maturation status. *J Contemp Dent Pract* 2018;19:662-
537 668.
538
- 539 34. Nimigean V, Sîrbu VD, Nimigean VR, Bădiță DG, Poll A, Moraru SA, Păun
540 DL. Morphological assessment of the mandibular canal trajectory in edentate
541 subjects. *Rom J Morphol Embryol* 2018;59:235-242.
542
- 543 35. Zheng J, Ni S, Wang Y, Zhang B, Teng Y, Jiang S. Sex determination of Han
544 adults in Northeast China using cone beam computer tomography. *Forensic Sci Int*
545 2018;289:450.e1-450.e7.
546
- 547 36. Rostetter C, Hungerbühler A, Blumer M, Rucker M, Wagner M, Stadlinger B,
548 Lübbers HT. Cone beam computed tomography evaluation of the artery in the lateral
549 wall of the maxillary sinus: retrospective analysis of 602 sinuses. *Implant Dent*
550 2018;27:434-438.
551
- 552 37. Goyushov S, Tözüm MD, Tözüm TF. Assessment of morphological and
553 anatomical characteristics of mental foramen using cone beam computed
554 tomography. *Surg Radiol Anat* 2018;40:1133-1139.
555
- 556 38. Ridel AF, Demeter F, Liebenberg J, L'Abbé EN, Vandermeulen D, Oettté AC.
557 Skeletal dimensions as predictors for the shape of the nose in a South African
558 sample: A cone-beam computed tomography (CBCT) study. *Forensic Sci Int*
559 2018;289:18-26.
560
- 561 39. do Carmo Oliveira M, Tedesco TK, Gimenez T, Allegrini S Jr. Analysis of the
562 frequency of visualization of morphological variations in anatomical bone features
563 in the mandibular interforaminal region through cone-beam computed tomography.
564 *Surg Radiol Anat* 2018;40:1119-1131.
565
- 566 40. Fan L, Yuan K, Niu C, Ma R, Huang Z. A cone-beam computed tomography
567 study of the mesial cervical concavity of maxillary first premolars. *Arch Oral Biol*
568 2018;92:79-82.
569
- 570 41. Goller Bulut D, Köse E. Available bone morphology and status of neural
571 structures in the mandibular interforaminal region: three-dimensional analysis of
572 anatomical structures. *Surg Radiol Anat* 2018;40:1243-1252.
573

- 574 42. Niu L, Wang J, Yu H, Qiu L. New classification of maxillary sinus contours and
575 its relation to sinus floor elevation surgery. *Clin Implant Dent Relat Res*
576 2018;20:493-500.
577
- 578 43. Allam E, Mpofu P, Ghoneima A, Tuceryan M, Kula K. The relationship between
579 hard tissue and soft tissue dimensions of the nose in children: a 3D cone beam
580 computed tomography study. *J Forensic Sci* 2018;63:1652-1660.
581
- 582 44. de Castro MAA, Barra SG, Vich MOL, Abreu MHG, Mesquita RA. Mandibular
583 canal branching assessed with cone beam computed tomography. *Radiol Med*
584 2018;123:601-608.
585
- 586 45. J PC, Marimuthu T, C K, Devadoss P, Kumar SM. Prevalence and measurement
587 of anterior loop of the mandibular canal using CBCT: A cross sectional study. *Clin*
588 *Implant Dent Relat Res* 2018;20:531-534.
589
- 590 46. Rao JB, Tatuskar P, Pulla A, Kumar N, Patil SC, Tiwari I. Radiographic
591 assessment of anatomy of nasopalatine canal for dental implant Placement: a cone
592 beam computed tomographic study. *J Contemp Dent Pract* 2018;19:301-305.
593
- 594 47. Kikuta S, Iwanaga J, Nakamura K, Hino K, Nakamura M, Kusukawa J. The
595 retromolar canals and foramina: radiographic observation and application to oral
596 surgery. *Surg Radiol Anat* 2018;40:647-652.
597
- 598 48. Liu L, Kang BC, Yoon SJ, Lee JS, Hwang SA. Radiographic features of lingual
599 mandibular bone depression using dental cone beam computed tomography.
600 *Dentomaxillofac Radiol* 2018;47:20170383.
601
- 602 49. Krohn S, Brockmeyer P, Kubein-Meesenburg D, Kirschneck C, Buegers R.
603 Elongated styloid process in patients with temporomandibular disorders - Is there a
604 link? *Ann Anat* 2018;217:118-124.
605
- 606 50. Zahedi S, Mostafavi M, Lotfirikan N. Anatomic study of mandibular posterior
607 teeth using cone-beam computed tomography for endodontic surgery. *J Endod*
608 2018;44:738-743.
609
- 610 51. Krishnan U, Monsour P, Thaha K, Lalloo R, Moule A. A limited field cone-
611 beam computed tomography-based evaluation of the mental foramen, accessory
612 mental foramina, anterior loop, lateral lingual foramen, and lateral lingual canal. *J*
613 *Endod* 2018;44:946-951.
614
- 615 52. Aksoy U, Orhan K. Association between odontogenic conditions and maxillary
616 sinus mucosal thickening: a retrospective CBCT study. *Clin Oral Investig*
617 2019;23:123-131.

- 618
619 53. Bayrak S, Kurşun-Çakmak EŞ, Atakan C, Orhan K. Anatomic study on
620 sphenoidal emissary foramen by using cone-beam computed tomography. *J*
621 *Craniofac Surg* 2018;29:e477-e480.
622
- 623 54. Alfawaz H, Alqedairi A, Alkhayyal AK, Almobarak AA, Alhusain MF, Martins
624 JNR. Prevalence of C-shaped canal system in mandibular first and second molars in
625 a Saudi population assessed via cone beam computed tomography: a retrospective
626 study. *Clin Oral Investig* 2019;23:107-112.
627
- 628 55. Shah NP, Murtadha L, Brown J. Bifurcation of the inferior dental nerve canal: an
629 anatomical study. *Br J Oral Maxillofac Surg* 2018;56:267-271.
630
- 631 56. Sava CJ, Rusu MC, Săndulescu M, Dincă D. Vertical and sagittal combinations
632 of concha bullosa media and paradoxical middle turbinate. *Surg Radiol Anat*
633 2018;40:847-853.
634
- 635 57. Ding X, Suzuki S, Shiga M, Ohbayashi N, Kurabayashi T, Moriyama K.
636 Evaluation of tongue volume and oral cavity capacity using cone-beam computed
637 tomography. *Odontology* 2018;106:266-273.
638
- 639 58. Pilloni A, Rotundo R, Gambarini G, Testarelli L, Dell'olmo F. Bone dehiscences
640 and fenestrations of the anterior mandibular facial bone wall: a retrospective cone
641 beam computed tomography study. *Minerva Stomatol* 2018;67:86-95.
642
- 643 59. Lvovsky A, Bachrach S, Kim HC, Pawar A, Levinzon O, Ben Itzhak J,
644 Solomonov M. Relationship between root apices and the mandibular canal: a cone-
645 beam computed tomographic comparison of 3 populations. *J Endod* 2018;44:555-
646 558.
647
- 648 60. Bayrak S, Ustaoglu G, Demiralp KÖ, Kurşun Çakmak EŞ. Evaluation of the
649 characteristics and association between Schneiderian membrane thickness and nasal
650 septum deviation. *J Craniofac Surg* 2018;29:683-687.
651
- 652 61. Gümüşok M, Akarslan ZZ, Başman A, Üçok Ö. Evaluation of accessory mental
653 foramina morphology with cone-beam computed tomography. *Niger J Clin Pract*
654 2017;20:1550-1554.
655
- 656 62. Martins JNR, Ordinola-Zapata R, Marques D, Francisco H, Caramês J.
657 Differences in root canal system configuration in human permanent teeth within
658 different age groups. *Int Endod J* 2018;51:931-941.
659
- 660 63. Sanchez-Perez A, Boix-Garcia P, Lopez-Jornet P. Cone-Beam CT assessment of
661 the position of the medial lingual foramen for dental implant placement in the

- 662 anterior symphysis. *Implant Dent* 2018;27:43-48.
663
664 64. Chen YC, Tsai CL, Chen YC, Chen G, Yang SF. A cone-beam computed
665 tomography study of C-shaped root canal systems in mandibular second premolars
666 in a Taiwan Chinese subpopulation. *J Formos Med Assoc* 2018;117:1086-1092.
667
668 65. Haghanifar S, Moudi E, Bijani A, Ghanbarabadi MK. Morphologic assessment
669 of mandibular anterior teeth root canal using CBCT. *Acta Med Acad* 2017;46:85-93.
670
671 66. Borghesi A, Pezzotti S, Nocivelli G, Maroldi R. Five mental foramina in the
672 same mandible: CBCT findings of an unusual anatomical variant. *Surg Radiol Anat*
673 2018;40:635-640.
674
675 67. Ghandourah AO, Rashad A, Heiland M, Hamzi BM, Friedrich RE. Cone-beam
676 tomographic analysis of canalis sinuosus accessory intraosseous canals in the
677 maxilla. *Ger Med Sci* 2017;15:Doc20.
678
679 68. Aksoy U, Aksoy S, Orhan K. A cone-beam computed tomography study of the
680 anatomical relationships between mandibular teeth and the mandibular canal, with a
681 review of the current literature. *Microsc Res Tech* 2018;81:308-314.
682
683 69. Olczak K, Pawlicka H. The morphology of maxillary first and second molars
684 analyzed by cone-beam computed tomography in a polish population. *BMC Med*
685 *Imaging* 2017;17:68.
686
687 70. Bonta H, Carranza N, Gualtieri AF, Rojas MA. Morphological characteristics of
688 the facial bone wall related to the tooth position in the alveolar crest in the maxillary
689 anterior. *Acta Odontol Latinoam* 2017;30:49-56.
690
691 71. Talo Yildirim T, Güncü GN, Colak M, Nares S, Tözüm TF. Evaluation of
692 maxillary sinus septa: a retrospective clinical study with cone beam computerized
693 tomography (CBCT). *Eur Rev Med Pharmacol Sci* 2017;21:5306-5314.
694
695 72. Ketterer MC, Aschendorff A, Arndt S, Hassepass F, Wesarg T, Laszig R, Beck
696 R. The influence of cochlear morphology on the final electrode array position. *Eur*
697 *Arch Otorhinolaryngol* 2018;275:385-394.
698
699 73. AlTarawneh S, AlHadidi A, Hamdan AA, Shaqman M, Habib E. Assessment of
700 bone dimensions in the anterior maxilla: A cone beam computed tomography study.
701 *J Prosthodont* 2018;27:321-328.
702
703 74. Lim EL, Ngeow WC, Lim D. The implications of different lateral wall
704 thicknesses on surgical access to the maxillary sinus. *Braz Oral Res* 2017;31:e97.
705

- 706 75. Studebaker B, Hollender L, Mancl L, Johnson JD, Paranjpe A. The Incidence of
707 second mesiobuccal canals located in maxillary molars with the aid of cone-beam
708 computed tomography. *J Endod* 2018;44:565-570.
709
- 710 76. Ali IK, Sansare K, Karjodkar FR, Salve P. Cone beam computed tomography
711 assessment of accessory Infraorbital foramen and determination of infraorbital
712 foramen position. *J Craniofac Surg* 2018;29:e124-e126.
713
- 714 77. Al-Ghurabi ZH, Abdulrazaq SS. Vascular precautions before sinus lift
715 procedure. *J Craniofac Surg* 2018;29:e116-e118.
716
- 717 78. Gu L, Zhu C, Chen K, Liu X, Tang Z. Anatomic study of the position of the
718 mandibular canal and corresponding mandibular third molar on cone-beam
719 computed tomography images. *Surg Radiol Anat* 2018;40:609-614.
720
- 721 79. Wu YC, Cheng WC, Chung MP, Su CC, Weng PW, Cathy Tsai YW, Chiang
722 HS, Yeh HW, Chung CH, Shieh YS, Huang RY. Complicated root canal
723 morphology of mandibular lateral incisors is associated with the presence of
724 distolingual root in mandibular first molars: a cone-beam computed tomographic
725 study in a Taiwanese population. *J Endod* 2018;44:73-79.
726
- 727 80. Sun R, Cai Y, Yuan Y, Zhao JH. The characteristics of adjacent anatomy of
728 mandibular third molar germs: a CBCT study to assess the risk of extraction. *Sci*
729 *Rep* 2017;7:14154.
730
- 731 81. Dagistan S, Miloğlu Ö, Altun O, Umar EK. Retrospective morphometric
732 analysis of the infraorbital foramen with cone beam computed tomography. *Niger J*
733 *Clin Pract* 2017;20:1053-1064.
734
- 735 82. Sun W, Liu A, Gong Y, Shu R, Xie Y. Evaluation of the anastomosis canal in
736 lateral maxillary sinus wall with cone beam computerized tomography: a clinical
737 study. *J Oral Implantol* 2018;44:5-13.
738
- 739 83. Srebrzyńska-Witek A, Koszowski R, Różyło-Kalinowska I. Relationship
740 between anterior mandibular bone thickness and the angulation of incisors and
741 canines-a CBCT study. *Clin Oral Investig* 2018;22:1567-1578.
742
- 743 84. Ratanajirasut R, Panichuttra A, Panmekiate S. A cone-beam computed
744 tomographic study of root and canal morphology of maxillary first and second
745 permanent molars in a Thai population. *J Endod* 2018;44:56-61.
746
- 747 85. Štoković N, Trkulja V, Čuković-Bagić I, Lauc T, Grgurević L. Anatomical
748 variations of the frontal sinus and its relationship with the orbital cavity. *Clin Anat*
749 2018;31:576-582.
750

- 751 86. Zhang Y, Xu H, Wang D, Gu Y, Wang J, Tu S, Qiu X, Zhang F, Luo Y, Xu S,
752 Bai J, Simone G, Zhang G. Assessment of the second mesiobuccal root canal in
753 maxillary first molars: a cone-beam computed tomographic study. *J Endod*
754 2017;43:1990-1996.
755
- 756 87. Yildirim TT, Güncü GN, Gökşülük D, Tözüm MD, Colak M, Tözüm TF. The
757 effect of demographic and disease variables on Schneiderian membrane thickness
758 and appearance. *Oral Surg Oral Med Oral Pathol Oral Radiol* 2017;124:568-576.
759
- 760 88. Alam MK, Alhabib S, Alzarea BK, Irshad M, Faruqi S, Sghaireen MG, Patil S,
761 Basri R. 3D CBCT morphometric assessment of mental foramen in Arabic
762 population and global comparison: imperative for invasive and non-invasive
763 procedures in mandible. *Acta Odontol Scand* 2018;76:98-104.
764
- 765 89. Li Y, Yang X, Zhang B, Wei B, Gong Y. Detection and characterization of the
766 accessory mental foramen using cone-beam computed tomography. *Acta Odontol*
767 *Scand* 2018;76:77-85.
768
- 769 90. Rusu MC, Măru N, Săndulescu M, Sava CJ. Rare anatomic variation: true bifid
770 inferior turbinate. *Surg Radiol Anat* 2018;40:217-220.
771
- 772 91. Yeung AWK, Tanaka R, Khong PL, von Arx T, Bornstein MM. Frequency,
773 location, and association with dental pathology of mucous retention cysts in the
774 maxillary sinus. A radiographic study using cone beam computed tomography
775 (CBCT). *Clin Oral Investig* 2018;22:1175-1183.
776
- 777 92. Wang Y, Qiu Y, Liu H, He J, Fan X. Quantitative evaluation of palatal bone
778 thickness for the placement of orthodontic miniscrews in adults with different facial
779 types. *Saudi Med J* 2017;38:1051-1057.
780
- 781 93. Santos AR, Castellucci M, Crusoé-Rebello IM, Sobral MC. Assessing bone
782 thickness in the infrazygomatic crest area aiming the orthodontic miniplates
783 positioning: a tomographic study. *Dental Press J Orthod* 2017;22:70-76.
784
- 785 94. Zand V, Mokhtari H, Zonouzi HR, Shojaei SN. Root canal morphologies of
786 mesiobuccal roots of maxillary molars using cone beam computed tomography and
787 periapical radiographic techniques in an Iranian population. *J Contemp Dent Pract*
788 2017;18:745-749.
789
- 790 95. Petitjean E, Mavridou A, Li X, Hauben E, Cotti E, Lambrechts P. Multimodular
791 assessment of a calcified extraradicular deposit on the root surfaces of a mandibular
792 molar. *Int Endod J* 2018;51:375-385.
793
- 794 96. Akbarzadeh N, Aminoshariae A, Khalighinejad N, Palomo JM, Syed A, Kulild
795 JC, Sadeghi G, Mickel A. The Association between the anatomic landmarks of the

- 796 pulp chamber floor and the prevalence of middle mesial canals in mandibular first
797 molars: an in vivo analysis. *J Endod* 2017;43:1797-1801.
- 798
- 799 97. Kim SH, Shin SM, Choi YS, Ko CC, Kim SS, Park SB, Son WS, Kim YI.
800 Morphometric analysis of the maxillary root apex positions according to crowding
801 severity. *Orthod Craniofac Res* 2017;20:202-208.
- 802
- 803 98. Wang M, Sun Y, Yu Y, Ding X. Evaluation of palatal bone thickness for
804 insertion of orthodontic mini-implants in adults and adolescents. *J Craniofac Surg*
805 2017;28:1468-1471.
- 806
- 807 99. Voon YS, Patil PG. Safe zone in anterior mandible related to the genial tubercle
808 for implant osteotomy in a Chinese-Malaysian population: A CBCT study. *J*
809 *Prosthet Dent* 2018;119:568-573.
- 810
- 811 100. Alhazmi A, Vargas E, Palomo JM, Hans M, Latimer B, Simpson S. Timing and
812 rate of spheno-occipital synchondrosis closure and its relationship to puberty. *PLoS*
813 *One* 2017;12:e0183305. Erratum in: *PLoS One* 2018;13:e0191703.
- 814
- 815 101. Rusu MC, Săndulescu M, Bichir C, Muntianu LAS. Combined anatomical
816 variations: The mylohyoid bridge, retromolar canal and accessory palatine canals
817 branched from the canalis sinuosus. *Ann Anat* 2017;214:75-79.
- 818
- 819 102. Muínelo-Lorenzo J, Fernández-Alonso A, Smyth-Chamosa E, Suárez-
820 Quintanilla JA, Varela-Mallou J, Suárez-Cunqueiro MM. Predictive factors of the
821 dimensions and location of mental foramen using cone beam computed tomography.
822 *PLoS One* 2017;12:e0179704.
- 823
- 824 103. Matsumura T, Ishida Y, Kawabe A, Ono T. Quantitative analysis of the
825 relationship between maxillary incisors and the incisive canal by cone-beam
826 computed tomography in an adult Japanese population. *Prog Orthod* 2017;18:24.
- 827
- 828 104. Lozano-Carrascal N, Salomó-Coll O, Gehrke SA, Calvo-Guirado JL,
829 Hernández-Alfaro F, Gargallo-Albiol J. Radiological evaluation of maxillary sinus
830 anatomy: A cross-sectional study of 300 patients. *Ann Anat* 2017;214:1-8.
- 831
- 832 105. Hiebert BM, Abramovitch K, Rice D, Torabinejad M. Prevalence of second
833 mesiobuccal canals in maxillary first molars detected using cone-beam computed
834 tomography, direct occlusal access, and coronal plane grinding. *J Endod*
835 2017;43:1711-1715.
- 836
- 837 106. Pérez-Heredia M, Ferrer-Luque CM, Bravo M, Castelo-Baz P, Ruíz-Piñón M,
838 Baca P. Cone-beam computed tomographic study of root anatomy and canal
839 configuration of molars in a Spanish population. *J Endod* 2017;43:1511-1516.
- 840

- 841 107. Wanzeler AMV, Renda MDO, de Oliveira Pereira ME, Alves-Junior SM, Tuji
842 FM. Anatomical relation between nasal septum deviation and oropharynx volume in
843 different facial patterns evaluated through cone beam computed tomography. *Oral*
844 *Maxillofac Surg* 2017;21:341-346.
- 845
846 108. Ring J, Ring KC. Rare root canal configuration of mandibular second premolar
847 using cone-beam computed tomographic scanning. *J Endod*. 2017;43:1897-1900.
- 848
849 109. Choi IGG, Duailibi-Neto EF, Beaini TL, da Silva RLB, Chilvarquer I. The
850 frontal sinus cavity exhibits sexual dimorphism in 3D cone-beam CT images and
851 can be used for sex determination. *J Forensic Sci* 2018;63:692-698.
- 852
853 110. Gopalakrishnan A, Unnikrishna K, Balan A, Haris PS. Use of cone-beam
854 computed tomography in the diagnosis and treatment of an unusual canine
855 abnormality. *Sultan Qaboos Univ Med J* 2017;17:e238-e240.
- 856
857 111. Atil F, Adisen MZ, Misirlioglu M, Suer BT. Stafne bone cavity complicated by
858 periapical Infection. *J Coll Physicians Surg Pak* 2016;26:109-110.
- 859
860 112. Wang X, Chen K, Wang S, Tiwari SK, Ye L, Peng L. Relationship between the
861 mental foramen, mandibular canal, and the surgical access line of the mandibular
862 posterior teeth: a cone-beam computed tomographic analysis.
863 *J Endod* 2017;43:1262-1266.
- 864
865 113. Scomparin L, Soares MQ, Rubira CM, Yaedú RY, Imada TS, Centurion BS,
866 Tolentino ES, Lauris JR, Rubira-Bullen IR. CBCT location of the fusion between
867 the buccal and lingual cortical in the mandibular ramus: importance to sagittal split
868 osteotomy. *Med Oral Patol Oral Cir Bucal* 2017;22:e500-e505.
- 869
870 114. Vinothkumar TS, Kandaswamy D, Arathi G, Ramkumar S, Felsypremila G.
871 Endodontic management of dilacerated maxillary central incisor fused to a
872 supernumerary tooth using cone beam computed tomography: an unusual clinical
873 presentation. *J Contemp Dent Pract* 2017;18:522-526.
- 874
875 115. Jang JK, Kwak SW, Ha JH, Kim HC. Anatomical relationship of maxillary
876 posterior teeth with the sinus floor and buccal cortex. *J Oral Rehabil* 2017;44:617-
877 625.
- 878
879 116. Zhang P, Wei X. Combined therapy for a rare case of type III dens invaginatus
880 in a mandibular central incisor with a periapical lesion: a case report. *J Endod*
881 2017;43:1378-1382.
- 882
883 117. Rojo-Sanchis J, Viña-Almunia J, Peñarrocha-Oltra D, Peñarrocha-Diago M.
884 Facial alveolar bone width at the first and second maxillary premolars in healthy

- 885 patients: a cone beam computed tomography study. *J Oral Implantol* 2017;43:261-
886 265.
- 887
- 888 118. Chaniotis A, Filippatos CG. The use of a novel approach for the
889 instrumentation of a cone-beam computed tomography-discernible lateral canal in
890 an unusual maxillary incisor: case report. *J Endod* 2017;43:1023-1027.
891
- 892 119. Nishihara K, Yoshimine SI, Goto T, Ishihata K, Kume KI, Yoshimura T,
893 Nakamura N, Arasaki A. Topographic analysis of the maxillary premolars relative to
894 the maxillary sinus and the alveolar bone using cone beam computed tomography.
895 *Oral Surg Oral Med Oral Pathol Oral Radiol* 2017;123:606-612.
896
- 897 120. Farahamnd A, Sarlati F, Eslami S, Ghassemian M, Youssefi N, Jafarzadeh
898 Esfahani B. Evaluation of impacting factors on facial bone thickness in the anterior
899 maxillary region. *J Craniofac Surg* 2017;28:700-705.
900
- 901 121. Martins JNR, Francisco H, Ordinola-Zapata R. Prevalence of C-shaped
902 configurations in the mandibular first and second premolars: a cone-beam computed
903 tomographic in vivo study. *J Endod* 2017;43:890-895.
904
- 905 122. Zoya-Farook A, Abhishek P, Shahabadi A. Cone-beam computed tomographic
906 evaluation and endodontic management of a mandibular first premolar with type IX
907 canal configuration: case report. *J Endod* 2017;43:1207-1213.
908
- 909 123. Sa SC, Melo SL, Melo DP, Freitas DQ, Campos PS. Relationship between
910 articular eminence inclination and alterations of the mandibular condyle: a CBCT
911 study. *Braz Oral Res* 2017;31:e25.
912
- 913 124. Tilen R, Patcas R, Bornstein MM, Ludwig B, Schätzle M. The nasopalatine
914 canal, a limiting factor for temporary anchorage devices: a cone beam computed
915 tomography data study. *Eur J Orthod* 2017;39:646-653.
916
- 917 125. Yang XW, Zhang FF, Li YH, Wei B, Gong Y. Characteristics of intrabony
918 nerve canals in mandibular interforaminal region by using cone-beam computed
919 tomography and a recommendation of safe zone for implant and bone harvesting.
920 *Clin Implant Dent Relat Res* 2017;19:530-538.
921
- 922 126. Pamboo J, Hans MK, Chander S, Sharma K. Endodontic management of
923 maxillary first molar with two palatal canals aided with cone beam computed
924 tomography: a case report. *Compend Contin Educ Dent* 2017;38:e1-e4.
925
- 926 127. Tan X, Zhang L, Zhou W, Li Y, Ning J, Chen X, Song D, Zhou X, Huang D.
927 Palatal radicular groove morphology of the maxillary incisors: a case series report. *J*
928 *Endod* 2017;43:827-833.
929

- 930 128. Pawar AM, Pawar M, Kfir A, Singh S, Salve P, Thakur B, Neelakantan P. Root
931 canal morphology and variations in mandibular second molar teeth of an Indian
932 population: an in vivo cone-beam computed tomography analysis. *Clin Oral Investig*
933 2017;21:2801-2809.
- 934
935 129. Caruso S, Storti E, Nota A, Ehsani S, Gatto R. Temporomandibular joint
936 anatomy assessed by CBCT images. *Biomed Res Int* 2017;2017:2916953.
- 937
938 130. Goergen MJ, Holton NE, Grünheid T. Morphological interaction between the
939 nasal septum and nasofacial skeleton during human ontogeny. *J Anat* 2017;230:689-
940 700.
- 941
942 131. Zmysłowska-Polakowska E, Radwański M, Łęski M, Ledzion S, Łukomska-
943 Szymańska M, Polgaj M. The assessment of accessory mental foramen in a selected
944 polish population: a CBCT study. *BMC Med Imaging* 2017;17:17.
- 945
946 132. Tavelli L, Borgonovo AE, Re D, Maiorana C. Sinus presurgical evaluation: a
947 literature review and a new classification proposal. *Minerva Stomatol* 2017;66:115-
948 131.
- 949
950 133. Mladina R, Antunović R, Cingi C, Bayar Muluk N, Skitarelić N. Sinus septi
951 nasi: anatomical study. *Clin Anat* 2017;30:312-317.
- 952
953 134. Borgonovo AE, Taschieri S, Vavassori V, Re D, Francetti L, Corbella S.
954 Incidence and characteristics of mandibular accessory canals: A radiographic
955 investigation. *J Investig Clin Dent* 2017;8.
- 956
957 135. Ko YC, Huang HL, Shen YW, Cai JY, Fuh LJ, Hsu JT. Variations in crestal
958 cortical bone thickness at dental implant sites in different regions of the jawbone.
959 *Clin Implant Dent Relat Res* 2017;19:440-446.
- 960
961 136. Taleghani F, Tehranchi M, Shahab S, Zohri Z. Prevalence, location, and size of
962 maxillary sinus septa: computed tomography scan analysis. *J Contemp Dent Pract*.
963 2017;18:11-15.
- 964
965 137. Sirbu VD, Perlea P, Nimigean VR, Bădiță DG, Șerban A, Nimigean V.
966 Morphological assessment of the mandibular canal trajectory in dentate subjects.
967 *Rom J Morphol Embryol* 2017;58:1401-1408.
- 968
969 138. He P, Truong MK, Adeeb N, Tubbs RS, Iwanaga J. Clinical anatomy and sur-
970 gical significance of the lingual foramina and their canals. *Clin Anat* 2017;30:194-
971 204.
- 972

- 973 139. Parker J, Mol A, Rivera EM, Tawil P. CBCT uses in clinical endodontics: the
974 effect of CBCT on the ability to locate MB2 canals in maxillary molars. *Int Endod J*
975 2017;50:1109-1115.
976
- 977 140. Jaitley M, Phulambrikar T, Kode M, Gupta A, Singh SK. Foramen magnum as
978 a tool for sexual dimorphism: A cone beam computed tomography study. *Indian J*
979 *Dent Res* 2016;27:458-462.
980
- 981 141. Buyuk SK, Sekerci AE, Benkli YA, Ekizer A. A survey of ponticulus posticus:
982 radiological analysis of atlas in an orthodontic population based on cone-beam
983 computed tomography. *Niger J Clin Pract* 2017;20:106-110.
984
- 985 142. Gungor E, Aglarci OS, Unal M, Dogan MS, Guven S. Evaluation of mental
986 foramen location in the 10-70 years age range using cone-beam computed
987 tomography. *Niger J Clin Pract* 2017;20:88-92.
988
- 989 143. Rapado-González O, Suárez-Quintanilla JA, Suárez-Cunqueiro MM.
990 Anatomical variations of the greater palatine canal in cone-beam computed
991 tomography. *Surg Radiol Anat* 2017;39:717-723.
992
- 993 144. Yasa Y, Ocak A, Bayrakdar IS, Duman SB, Gumussoy I. Morphometric
994 analysis of sella turcica using cone beam computed tomography. *J Craniofac Surg*
995 2017;28:e70-e74.
996
- 997 145. Betancourt P, Navarro P, Muñoz G, Fuentes R. Prevalence and location of the
998 secondary mesiobuccal canal in 1,100 maxillary molars using cone beam computed
999 tomography. *BMC Med Imaging* 2016;16:66.
1000
- 1001 146. Agbaje JO, de Castele EV, Salem AS, Anumendem D, Lambrichts I, Politis C.
1002 Tracking of the inferior alveolar nerve: its implication in surgical planning. *Clin*
1003 *Oral Investig* 2017;21:2213-2220.
1004
- 1005 147. Yasa Y, Bayrakdar IS, Ocak A, Duman SB, Dedeoglu N. Evaluation of sella
1006 turcica shape and dimensions in cleft subjects using cone-beam computed
1007 tomography. *Med Princ Pract* 2017;26:280-285.
1008
- 1009 148. Shemesh A, Levin A, Katzenell V, Itzhak JB, Levinson O, Avraham Z,
1010 Solomonov M. C-shaped canals-prevalence and root canal configuration by cone
1011 beam computed tomography evaluation in first and second mandibular molars-a
1012 cross-sectional study. *Clin Oral Investig* 2017;21:2039-2044.
1013
- 1014 149. Kabak SL, Zhuravleva NV, Melnichenko YM, Savrasova NA. Study of the
1015 mandibular incisive canal anatomy using cone beam computed tomography. *Surg*
1016 *Radiol Anat* 2017;39:647-655.
1017

- 1018 150. Rodrigues CT, Oliveira-Santos C, Bernardineli N, Duarte MA, Bramante CM,
1019 Minotti-Bonfante PG, Ordinola-Zapata R. Prevalence and morphometric analysis of
1020 three-rooted mandibular first molars in a Brazilian subpopulation. *J Appl Oral Sci*
1021 2016;24:535-542.
1022
- 1023 151. Caputo BV, Noro Filho GA, de Andrade Salgado DM, Moura-Netto C, Giovani
1024 EM, Costa C. Evaluation of the root canal morphology of molars by using cone-
1025 beam computed tomography in a Brazilian population: Part I. *J Endod*
1026 2016;42:1604-1607.
1027
- 1028 152. Monsarrat P, Arcaute B, Peters OA, Maury E, Telmon N, Georgelin-Gurgel M,
1029 Maret D. Interrelationships in the variability of root canal anatomy among the
1030 permanent teeth: a full-mouth approach by cone-beam CT. *PLoS One*
1031 2016;11:e0165329.
1032
- 1033 153. Celikten B, Tufenkci P, Aksoy U, Kalender A, Kermeoglu F, Dabaj P, Orhan
1034 K. Cone beam CT evaluation of mandibular molar root canal morphology in a
1035 Turkish Cypriot population. *Clin Oral Investig* 2016;20:2221-2226.
1036
- 1037 154. Güldner C, Diogo I, Bernd E, Dräger S, Mandapathil M, Teymoortash A,
1038 Negm H, Wilhelm T. Visualization of anatomy in normal and pathologic middle
1039 ears by cone beam CT. *Eur Arch Otorhinolaryngol* 2017;274:737-742.
1040
- 1041 155. Falcão CA, Albuquerque VC, Amorim NL, Freitas SA, Santos TC, Matos FT,
1042 Ferraz MA. Frequency of the mesiopalatal canal in upper first permanent molars
1043 viewed through computed tomography. *Acta Odontol Latinoam* 2016;29:54-59.
1044
- 1045 156. Borgonovo AE, Rigaldo F, Maiorana C, Grossi GB, Augusti D, Re D. CBCT
1046 evaluation of the tridimensional relationship between impacted lower third molar
1047 and the inferior alveolar nerve position. *Minerva Stomatol* 2017;66:9-19.
1048
- 1049 157. Tambawala SS, Karjodkar FR, Sansare K, Prakash N, Dora AC. Sexual dimor-
1050 phism of foramen magnum using cone beam computed tomography. *J Forensic Leg*
1051 *Med* 2016;44:29-34.
1052
- 1053 158. Cao D, Zhu L, Chen Y, Xie L, Yan B, Sun Z. Buccally impacted maxillary ca-
1054 nines increase the likelihood of root separation in adjacent first premolars. *Oral Dis*
1055 2017;23:36-41.
1056
- 1057 159. Xu D, Wang Z, Sun L, Lin Z, Wan L, Li Y, Lin X, Peng W, Zhang Z, Gao Y.
1058 Classification of the root position of the maxillary central incisors and its clinical
1059 significance in immediate implant placement. *Implant Dent* 2016;25:520-524.
1060
- 1061 160. Velasco-Torres M, Padiá-Molina M, Alarcón JA, O'Valle F, Catena A, Galin-
1062 do-Moreno P. Maxillary sinus dimensions with respect to the posterior superior

- 1063 alveolar artery decrease with tooth loss. *Implant Dent* 2016;25:464-470.
1064
- 1065 161. Villaça-Carvalho MF, Manhães LR Jr, de Moraes ME, Lopes SL. Prevalence of
1066 bifid mandibular canals by cone beam computed tomography. *Oral Maxillofac Surg*
1067 2016;20:289-294.
1068
- 1069 162. Hiremath H, Agarwal R, Hiremath V, Phulambrikar T. Evaluation of proximity
1070 of mandibular molars and second premolar to inferior alveolar nerve canal among
1071 central Indians: A cone-beam computed tomographic retrospective study.
1072 *Indian J Dent Res* 2016;27:312-316.
1073
- 1074 163. Sinanoglu A, Orhan K, Kursun S, Inceoglu B, Oztas B. Evaluation of optic
1075 canal and surrounding structures using cone beam computed tomography:
1076 considerations for maxillofacial surgery. *J Craniofac Surg* 2016;27:1327-1330.
1077
- 1078 164. Hourfar J, Bister D, Lisson JA, Goldbecher C, Ludwig B. Vestibulo-Oral
1079 inclination of maxillary and mandibular canines and bicuspid – a CBCT
1080 investigation. *Head Face Med* 2016;12:22.
1081
- 1082 165. Tolstunov L, Brickeen M, Kamanin V, Susarla SM, Selvi F. Is the angulation
1083 of mandibular third molars associated with the thickness of lingual bone? *Br J Oral*
1084 *Maxillofac Surg* 2016;54:914-919.
1085
- 1086 166. Friedrich RE, Bruhn M, Lohse C. Cone-beam computed tomography of the
1087 orbit and optic canal volumes. *J Craniomaxillofac Surg* 2016;44:1342-1349.
1088
- 1089 167. Rodricks D, Gupta A, Phulambrikar T, Singh SK, Sharma BK, Agrawal P.
1090 Anatomical and morphological characterization of the nasopalatine canal: a cone-
1091 beam computed tomography study. *Mymensingh Med J* 2016;25:349-356.
1092
- 1093 168. Danesh-Sani SA, Movahed A, ElChaar ES, Chong Chan K, Amintavakoli N.
1094 Radiographic evaluation of maxillary sinus lateral wall and posterior superior
1095 alveolar artery anatomy: a cone-beam computed tomographic study. *Clin Implant*
1096 *Dent Relat Res* 2017;19:151-160.
1097
- 1098 169. Ge ZP, Yang P, Li G, Zhang JZ, Ma XC. Age estimation based on pulp
1099 cavity/chamber volume of 13 types of tooth from cone beam computed tomography
1100 images. *Int J Legal Med* 2016;130:1159-1167.
1101
- 1102 170. Kong N, Hui M, Miao F, Yuan H, Du Y, Chen N. Mandibular incisive canal in
1103 Han Chinese using cone beam computed tomography. *Int J Oral Maxillofac Surg*
1104 2016;45:1142-1146.
1105
- 1106 171. Zhang D, Chen J, Lan G, Li M, An J, Wen X, Liu L, Deng M. The root canal
1107 morphology in mandibular first premolars: a comparative evaluation of cone-beam

- 1108 computed tomography and micro-computed tomography. Clin Oral Investig
1109 2017;21:1007-1012.
1110
- 1111 172. Koivisto T, Chiona D, Milroy LL, McClanahan SB, Ahmad M, Bowles WR.
1112 Mandibular canal location: cone-beam computed tomography examination. J Endod
1113 2016;42:1018-1021.
1114
- 1115 173. He X, Jiang J, Cai W, Pan Y, Yang Y, Zhu K, Zheng Y. Assessment of the
1116 appearance, location and morphology of mandibular lingual foramina using cone
1117 beam computed tomography. Int Dent J 2016;66:272-279.
1118
- 1119 174. Han SS, Hwang JJ, Jeong HG. Accessory mental foramina associated with
1120 neurovascular bundle in Korean population. Surg Radiol Anat 2016;38:1169-1174.
1121
- 1122 175. Manhães Júnior LR, Villaça-Carvalho MF, Moraes ME, Lopes SL, Silva MB,
1123 Junqueira JL. Location and classification of canalis sinuosus for cone beam
1124 computed tomography: avoiding misdiagnosis. Braz Oral Res 2016;30:e49.
1125
- 1126 176. Chong BS, Gohil K, Pawar R, Makdissi J. Anatomical relationship between
1127 mental foramen, mandibular teeth and risk of nerve injury with endodontic
1128 treatment. Clin Oral Investig 2017;21:381-387.
1129
- 1130 177. Estrela C, Nunes CA, Guedes OA, Alencar AH, Estrela CR, Silva RG, Pécora
1131 JD, Sousa-Neto MD. Study of anatomical relationship between posterior teeth and
1132 maxillary sinus floor in a subpopulation of the Brazilian central region using cone-
1133 beam computed tomography - Part 2. Braz Dent J 2016;27:9-15.
1134
- 1135 178. Tian XM, Yang XW, Qian L, Wei B, Gong Y. Analysis of the root and canal
1136 morphologies in maxillary first and second molars in a Chinese population using
1137 cone-beam computed tomography. J Endod 2016;42:696-701.
1138
- 1139 179. Ogawa A, Fukuta Y, Nakasato H, Nakasato S. Cone beam computed
1140 tomographic evaluation of nutrient canals and foramina in the anterior region of the
1141 mandible. Surg Radiol Anat 2016;38:1029-1032.
1142
- 1143 180. Zhang CY, DeBaz C, Bhandal G, Alli F, Buencamino Francisco MC, Thacker
1144 HL, Palomo JM, Palomo L. Buccal bone thickness in the esthetic zone of
1145 postmenopausal women: a CBCT analysis. Implant Dent 2016;25:478-484.
1146
- 1147 181. Jiang YY. Correlation between hyoid bone position and airway dimensions in
1148 Chinese adolescents by cone beam computed tomography analysis. Int J Oral
1149 Maxillofac Surg 2016;45:914-921.
1150

- 1151 182. Kim SR, Lee KM, Cho JH, Hwang HS. Three-dimensional prediction of the
1152 human eyeball and canthi for craniofacial reconstruction using cone-beam computed
1153 tomography. *Forensic Sci Int* 2016;261:164.e1-8.
1154
- 1155 183. Zeng C, Shen Y, Guan X, Wang X, Fan M, Li Y. Rare root canal configuration
1156 of bilateral maxillary second molar using cone-beam computed tomographic
1157 scanning. *J Endod* 2016;42:673-677.
1158
- 1159 184. Sanomiya Ikuta CR, Paes da Silva Ramos Fernandes LM, Poleti ML, Alvares
1160 Capelozza AL, Fischer Rubira-Bullen IR. Anatomical study of the posterior
1161 mandible: lateral lingual foramina in cone beam computed tomography. *Implant
1162 Dent* 2016;25:247-251.
1163
- 1164 185. Jayaratne YS, Zwahlen RA. The oropharyngeal airway in young adults with
1165 skeletal class II and class III deformities: a 3-D morphometric analysis. *PLoS One*
1166 2016;11:e0148086.
1167
- 1168 186. Agrawal PK, Wankhade J, Warhadpande M. A rare case of type III dens
1169 invaginatus in a mandibular second premolar and its nonsurgical endodontic
1170 management by using cone-beam computed tomography: a case report. *J Endod*
1171 2016;42:669-672.
1172
- 1173 187. Orhan K, Misirli M, Aksoy S, Seki U, Hincal E, Ormeci T, Arslan A.
1174 Morphometric analysis of the infraorbital foramen, canal and groove using cone
1175 beam CT: considerations for creating artificial organs. *Int J Artif Organs*
1176 2016;39:28-36.
1177
- 1178 188. Martins JN, Mata A, Marques D, Anderson C, Caramês J. Prevalence and
1179 characteristics of the maxillary C-shaped molar. *J Endod* 2016;42:383-389.
1180
- 1181 189. Blacher J, Van DaHuvel S, Parashar V, Mitchell JC. Variation in location of
1182 the mandibular foramen/inferior alveolar nerve complex given anatomic landmarks
1183 using cone-beam computed tomographic scans. *J Endod* 2016;42:393-396.
1184
- 1185 190. Codari M, Zago M, Guidugli GA, Pucciarelli V, Tartaglia GM, Ottaviani F,
1186 Righini S, Sforza C. The nasal septum deviation index (NSDI) based on CBCT data.
1187 *Dentomaxillofac Radiol* 2016;45:20150327.
1188
- 1189 191. Gamba Tde O, Alves MC, Haiter-Neto F. Mandibular sexual dimorphism
1190 analysis in CBCT scans. *J Forensic Leg Med* 2016;38:106-110.
1191
- 1192 192. Ge J, Zheng JW, Yang C, Qian WT. Variations in the buccal-lingual alveolar
1193 bone thickness of impacted mandibular third molar: our classification and treatment
1194 perspectives. *Sci Rep* 2016;6:16375.

1195
1196
1197
1198
1199
1200
1201
1202
1203
1204
1205
1206
1207
1208
1209
1210
1211
1212
1213
1214
1215
1216
1217
1218
1219
1220
1221
1222
1223
1224
1225
1226
1227
1228
1229
1230
1231
1232
1233
1234
1235
1236
1237

193. Yilmaz HG, Ayali A. Evaluation of the neurovascular bundle position at the palate with cone beam computed tomography: an observational study. *Head Face Med* 2015;11:39.

194. Yue W, Kim E. Nonsurgical endodontic management of a molar-incisor malformation-affected mandibular first molar: a case report. *J Endod* 2016;42:664-668.

195. Angelieri F, Franchi L, Cevidanes LH, McNamara JA Jr. Diagnostic performance of skeletal maturity for the assessment of midpalatal suture maturation. *Am J Orthod Dentofacial Orthop* 2015;148:1010-1016.

196. Măru N, Rusu MC, Săndulescu M. Variant anatomy of nasal turbinates: supreme, superior and middle conchae bullosae, paradoxical superior and inferior turbinates, and middle accessory turbinate. *Rom J Morphol Embryol* 2015;56:1223-1226.

197. Estrela C, Bueno MR, Couto GS, Rabelo LE, Alencar AH, Silva RG, Pécora JD, Sousa-Neto MD. Study of root canal anatomy in human permanent teeth in a subpopulation of Brazil's center region using cone-beam computed tomography - Part 1. *Braz Dent J* 2015;26:530-536.

198. Lyra CM, Delai D, Pereira KC, Pereira GM, Pasternak Júnior B, Oliveira CA. Morphology of mesiobuccal root canals of maxillary first molars: a comparison of CBCT scanning and cross-sectioning. *Braz Dent J* 2015;26:525-529.

199. Miles MS, Parks ET, Eckert GJ, Blanchard SB. Comparative evaluation of mandibular canal visibility on cross-sectional cone-beam CT images: a retrospective study. *Dentomaxillofac Radiol* 2016;45:20150296.

200. Ozcan G, Sekerci AE, Cantekin K, Aydinbelge M, Dogan S. Evaluation of root canal morphology of human primary molars by using CBCT and comprehensive review of the literature. *Acta Odontol Scand* 2016;74:250-258.

201. Khojastehpour L, Dehbozorgi M, Tabrizi R, Esfandnia S. Evaluating the anatomical location of the posterior superior alveolar artery in cone beam computed tomography images. *Int J Oral Maxillofac Surg* 2016;45:354-358.

202. Beshkenadze E, Chipashvili N. Anatomico-morphological features of the root canal system in Georgian population-cone beam computed tomography study. *Georgian Med News* 2015;(247):7-14.

- 1238 203. Levin A, Shemesh A, Katzenell V, Gottlieb A, Ben Itzhak J, Solomonov M.
1239 Use of cone-beam computed tomography during retreatment of a 2-rooted maxillary
1240 central incisor: case report of a complex diagnosis and treatment. *J Endod*
1241 2015;41:2064-2067.
- 1242
1243 204. Pereira-Maciel P, Tavares-de-Sousa E, Oliveira-Sales MA. The mandibular
1244 incisive canal and its anatomical relationships: a cone beam computed tomography
1245 study. *Med Oral Patol Oral Cir Bucal* 2015;20:e723-728.
- 1246
1247 205. Muinelo-Lorenzo J, Suárez-Quintanilla JA, Fernández-Alonso A, Varela-
1248 Mallou J, Suárez-Cunqueiro MM. Anatomical characteristics and visibility of
1249 mental foramen and accessory mental foramen: panoramic radiography vs. cone
1250 beam CT. *Med Oral Patol Oral Cir Bucal* 2015;20:e707-714.
- 1251
1252 206. Monsour P, Huang T. Morphology of the greater palatine grooves of the hard
1253 palate: a cone beam computed tomography study. *Aust Dent J* 2016;61:329-332.
- 1254
1255 207. Tao J, Wu J, Zhang X. Mandibular condylar morphology for bruxers with
1256 different grinding patterns. *Cranio* 2016;34:219-226.
- 1257
1258 208. Çakur B, Yaşa Y. Correlation between tinnitus and petrotympanic fissure status
1259 among patients with temporomandibular joint dysfunction. *J Oral Maxillofac Surg*
1260 2016;74:47-52.
- 1261
1262 209. Özçakır-Tomruk C, Dölekoğlu S, Özkurt-Kayahan Z, İlgü D. Evaluation of
1263 morphology of the nasopalatine canal using cone-beam computed tomography in a
1264 subgroup of Turkish adult population. *Surg Radiol Anat* 2016;38:65-70.
- 1265
1266 210. Varela-Centelles P, Loira-Gago M, Seoane-Romero JM, Takkouche B,
1267 Monteiro L, Seoane J. Detection of the posterior superior alveolar artery in the
1268 lateral sinus wall using computed tomography/cone beam computed tomography: a
1269 prevalence meta-analysis study and systematic review. *Int J Oral Maxillofac Surg*
1270 2015;44:1405-1410.
- 1271
1272 211. Dalmau E, Zamora N, Tarazona B, Gandia JL, Paredes V. A comparative study
1273 of the pharyngeal airway space, measured with cone beam computed tomography,
1274 between patients with different craniofacial morphologies. *J Craniomaxillofac Surg*
1275 2015;43:1438-446.
- 1276
1277 212. Dong H, Deng M, Wang W, Zhang J, Mu J, Zhu G. Sexual dimorphism of the
1278 mandible in a contemporary Chinese Han population. *Forensic Sci Int* 2015;255:9-
1279 15.
- 1280

- 1281 213. Friedrich RE, Laumann F, Zrnc T, Assaf AT. The nasopalatine canal in adults
1282 on cone beam computed tomograms-a clinical study and review of the literature. In
1283 Vivo 2015;29:467-486.
1284
- 1285 214. Rapado-González O, Suárez-Quintanilla JA, Otero-Cepeda XL, Fernández-
1286 Alonso A, Suárez-Cunqueiro MM. Morphometric study of the greater palatine canal:
1287 cone-beam computed tomography. Surg Radiol Anat 2015;37:1217-1224.
1288
- 1289 215. Kolsuz ME, Orhan K, Bilecenoglu B, Sakul BU, Ozturk A. Evaluation of
1290 genial tubercle anatomy using cone beam computed tomography. J Oral Sci
1291 2015;57:151-156.
1292
- 1293 216. Zhang W, Skrypczak A, Weltman R. Anterior maxilla alveolar ridge dimension
1294 and morphology measurement by cone beam computerized tomography (CBCT) for
1295 immediate implant treatment planning. BMC Oral Health 2015;15:65.
1296
- 1297 217. Zhang S, Shi X, Liu H. Angulations of anterior teeth with reference to the
1298 alveolar bone measured by CBCT in a Chinese population. Implant Dent
1299 2015;24:397-401.
1300
- 1301 218. Valente NA. Anatomical considerations on the alveolar antral artery as related
1302 to the sinus augmentation surgical procedure. Clin Implant Dent Relat Res
1303 2016;18:1042-1050.
1304
- 1305 219. Tian J, Liang G, Qi W, Jiang H. Odontogenic cutaneous sinus tract associated
1306 with a mandibular second molar having a rare distolingual root: a case report. Head
1307 Face Med 2015;11:13.
1308
- 1309 220. Štoković N, Trkulja V, Dumić-Čule I, Čuković-Bagić I, Lauc T, Vukičević S,
1310 Grgurević L. Sphenoid sinus types, dimensions and relationship with surrounding
1311 structures. Ann Anat 2016;203:69-76.
1312
- 1313 221. Carruth P, He J, Benson BW, Schneiderman ED. Analysis of the size and
1314 position of the mental foramen using the CS 9000 cone-beam computed
1315 tomographic unit. J Endod 2015;41:1032-1036.
1316
- 1317 222. Rusu MC, Săndulescu M, Ilie OC. Infraorbital canal bilaterally replaced by a
1318 lateroantral canal. Surg Radiol Anat 2015;37:1149-1153.
1319
- 1320 223. Fernández-Alonso A, Suárez-Quintanilla JA, Rapado-González O, Suárez-
1321 Cunqueiro MM. Morphometric differences of nasopalatine canal based on 3D
1322 classifications: descriptive analysis on CBCT. Surg Radiol Anat 2015;37:825-833.
1323

- 1324 224. Yilmaz HG, Boke F, Ayali A. Cone-beam computed tomography evaluation of
1325 the soft tissue thickness and greater palatine foramen location in the palate. *J Clin*
1326 *Periodontol* 2015;42:458-461.
1327
- 1328 225. Didilescu AC, Rusu MC, Săndulescu M. A rare case of impacted maxillary first
1329 premolar. *Surg Radiol Anat* 2015;37:1145-1147.
1330
- 1331 226. Al-koshab M, Nambiar P, John J. Assessment of condyle and glenoid fossa
1332 morphology using CBCT in South-East Asians. *PLoS One* 2015;10:e0121682.
1333
- 1334 227. Nosrat A, Schneider SC. Endodontic management of a maxillary lateral incisor
1335 with 4 root canals and a dens invaginatus tract. *J Endod* 2015;41:1167-1171.
1336
- 1337 228. Holmes PB, Wolf BJ, Zhou J. A CBCT atlas of buccal cortical bone thickness
1338 in interradicular spaces. *Angle Orthod* 2015;85:911-919.
1339
- 1340 229. Kim SY, Kim BS, Kim Y. Mandibular second molar root canal morphology
1341 and variants in a Korean subpopulation. *Int Endod J* 2016;49:136-144.
1342
- 1343 230. Jiang YY, Xu X, Su HL, Liu DX. Gender-related difference in the upper
1344 airway dimensions and hyoid bone position in Chinese Han children and adolescents
1345 aged 6-18 years using cone beam computed tomography. *Acta Odontol Scand*
1346 *2015;73:391-400.*
1347
- 1348 231. Perlea P, Nistor CC, Suciuc I, Iliescu MG, Iliescu AA. Rare multiple internal
1349 root resorption associated with perforation - a case report. *Rom J Morphol Embryol*
1350 *2014;55:1477-1481.*
1351
- 1352 232. Capar ID, Ertas H, Arslan H, Tarim Ertas E. A retrospective comparative study
1353 of cone-beam computed tomography versus rendered panoramic images in
1354 identifying the presence, types, and characteristics of dens invaginatus in a Turkish
1355 population. *J Endod* 2015;41:473-478.
1356
- 1357 233. De Angelis D, Gibelli D, Gaudio D, Cipriani Noce F, Guercini N, Varvara G,
1358 Sguazza E, Sforza C, Cattaneo C. Sexual dimorphism of canine volume: a pilot
1359 study. *Leg Med (Tokyo)* 2015;17:163-166.
1360
- 1361 234. Nickenig HJ, Wichmann M, Eitner S, Zöller JE, Kreppel M. Lingual
1362 concavities in the mandible: a morphological study using cross-sectional analysis
1363 determined by CBCT. *J Craniomaxillofac Surg* 2015;43:254-259.
1364
- 1365 235. Newaz ZA, Barghan S, Katkar RA, Bennett JA, Nair MK. Incidental findings
1366 of skull-base abnormalities in cone-beam computed tomography scans with

- 1367 consultation by maxillofacial radiologists. *Am J Orthod Dentofacial Orthop*
1368 2015;147:127-131.
- 1369
- 1370 236. Cunha RS, Junaid A, Mello I. Unilateral fusion of a supernumerary tooth to a
1371 maxillary permanent lateral incisor: a report of a rare case. *J Endod* 2015;41:420-
1372 423.
- 1373
- 1374 237. Sekerci AE, Soylyu E, Arikan MP, Aglarci OS. Is there a relationship between
1375 the presence of ponticulus posticus and elongated styloid process? *Clin Imaging*
1376 2015;39:220-224.
- 1377
- 1378 238. Bayrakdar IS, Miloglu O, Altun O, Gumusoy I, Durna D, Yilmaz AB. Cone
1379 beam computed tomography imaging of ponticulus posticus: prevalence,
1380 characteristics, and a review of the literature. *Oral Surg Oral Med Oral Pathol Oral*
1381 *Radiol* 2014;118:e210-219.
- 1382
- 1383 239. Friedlander AH, Liebeskind DS, Tran HQ, Mallya SM. What are the potential
1384 implications of identifying intracranial internal carotid artery atherosclerotic lesions
1385 on cone-beam computed tomography? A systematic review and illustrative case
1386 studies. *J Oral Maxillofac Surg* 2014;72:2167-2177.
- 1387
- 1388 240. López Jornet P, Boix P, Sanchez Perez A, Boracchia A. Morphological
1389 characterization of the anterior palatine region using cone beam computed
1390 tomography. *Clin Implant Dent Relat Res* 2015;17:e459-464.
- 1391
- 1392 241. Huang YD, Wu J, Sheu RJ, Chen MH, Chien DL, Huang YT, Huang CC, Chen
1393 YJ. Evaluation of the root and root canal systems of mandibular first premolars in
1394 northern Taiwanese patients using cone-beam computed tomography. *J Formos Med*
1395 *Assoc* 2015;114:1129-1134.
- 1396
- 1397 242. Sabir H, Kumbhare S, Rout P. Evaluation of ponticulus posticus on digital
1398 lateral cephalograms and cone beam computed tomography in patients with
1399 migraine and healthy individuals: a comparative study. *Oral Surg Oral Med Oral*
1400 *Pathol Oral Radiol* 2014;118:348-354.
- 1401
- 1402 243. Chong BS, Quinn A, Pawar RR, Makdissi J, Sidhu SK. The anatomical
1403 relationship between the roots of mandibular second molars and the inferior alveolar
1404 nerve. *Int Endod J* 2015;48:549-555.
- 1405
- 1406 244. Han T, Ma Y, Yang L, Chen X, Zhang X, Wang Y. A study of the root canal
1407 morphology of mandibular anterior teeth using cone-beam computed tomography in
1408 a Chinese subpopulation. *J Endod* 2014;40:1309-1314.
- 1409

- 1410 245. Acar B, Kamburoğlu K. Morphological and volumetric evaluation of the
1411 nasopalatal canal in a Turkish population using cone-beam computed tomography.
1412 Surg Radiol Anat 2015;37:259-265.
1413
- 1414 246. Çağlayan F, Sümbüllü MA, Miloğlu Ö, Akgül HM. Are all soft tissue
1415 calcifications detected by cone-beam computed tomography in the submandibular
1416 region sialoliths? J Oral Maxillofac Surg 2014;72:1531.
1417
- 1418 247. Mahdian M, Moghaddam EJ, Alzahrani A, Rengasamy K, Tadinada A.
1419 Calcification of the stylohyoid ligament in panoramic radiography and cone beam
1420 computed tomography among patients referred for dental implant treatment
1421 planning. Implant Dent 2014;23:508-513.
1422
- 1423 248. Miles DA, Danforth RA. Reporting findings in the cone beam computed
1424 tomography volume. Dent Clin North Am 2014;58:687-709.
1425
- 1426 249. Parks ET. Cone beam computed tomography for the nasal cavity and paranasal
1427 sinuses. Dent Clin North Am 2014;58:627-651.
1428
- 1429 250. Angelopoulos C. Anatomy of the maxillofacial region in the three planes of
1430 section. Dent Clin North Am 2014;58:497-521.
1431
- 1432 251. Nascimento HA, Visconti MA, Macedo Pde T, Haiter-Neto F, Freitas DQ.
1433 Evaluation of the zygomatic bone by cone beam computed tomography. Surg Radiol
1434 Anat 2015;37:55-60.
1435
- 1436 252. Sinanoglu A, Helvacioğlu-Yigit D. Analysis of C-shaped canals by panoramic
1437 radiography and cone-beam computed tomography: root-type specificity by
1438 longitudinal distribution. J Endod 2014;40:917-921.
1439
- 1440 253. Shiki K, Tanaka T, Kito S, Wakasugi-Sato N, Matsumoto-Takeda S, Oda M,
1441 Nishimura S, Morimoto Y. The significance of cone beam computed tomography
1442 for the visualization of anatomical variations and lesions in the maxillary sinus for
1443 patients hoping to have dental implant-supported maxillary restorations in a private
1444 dental office in Japan. Head Face Med 2014;10:20.
1445
- 1446 254. Ok E, Güngör E, Colak M, Altunsoy M, Nur BG, Ağlarci OS. Evaluation of the
1447 relationship between the maxillary posterior teeth and the sinus floor using cone-
1448 beam computed tomography. Surg Radiol Anat 2014;36:907-914.
1449
- 1450 255. Ok E, Altunsoy M, Nur BG, Ağlarci OS, Çolak M, Güngör E. A cone-beam
1451 computed tomography study of root canal morphology of maxillary and mandibular
1452 premolars in a Turkish population. Acta Odontol Scand 2014;72:701-706.
1453

- 1454 256. Sekerci AE, Sisman Y, Payveren MA. Evaluation of location and dimensions
1455 of mandibular lingual foramina using cone-beam computed tomography. *Surg*
1456 *Radiol Anat* 2014;36:857-864.
1457
- 1458 257. Nicolielo LF, Van Dessel J, Jacobs R, Martens W, Lambrechts I, Rubira-Bullen
1459 IR. Presurgical CBCT assessment of maxillary neurovascularization in relation to
1460 maxillary sinus augmentation procedures and posterior implant placement. *Surg*
1461 *Radiol Anat* 2014;36:915-924.
1462
- 1463 258. Vier-Pelisser FV, Morgental RD, Fritscher G, Ghisi AC, Borba MG, Scarparo
1464 RK. Management of type III dens invaginatus in a mandibular premolar: a case
1465 report. *Braz Dent J* 2014;25:73-78.
1466
- 1467 259. Sekerci AE, Cantekin K, Aydinbelge M. Cone beam computed tomographic
1468 analysis of neurovascular anatomical variations other than the nasopalatine canal in
1469 the anterior maxilla in a pediatric population. *Surg Radiol Anat* 2015;37:181-186.
1470
- 1471 260. Muínelo-Lorenzo J, Suárez-Quintanilla JA, Fernández-Alonso A, Marsillas-
1472 Rascado S, Suárez-Cunqueiro MM. Descriptive study of the bifid mandibular canals
1473 and retromolar foramina: cone beam CT vs panoramic radiography. *Dentomaxillofac Radiol* 2014;43:20140090.
1474
1475
- 1476 261. Park JB, Lee JE, Kim K, Yoo JT, Kim Y, Kook YA, Ko Y. The thickness of
1477 alveolar bone at the mandibular canine and premolar teeth in normal occlusion. *J*
1478 *Craniofac Surg* 2014;25:1115-1119.
1479
- 1480 262. Wanzeler AM, Marinho CG, Alves Junior SM, Manzi FR, Tuji FM.
1481 Anatomical study of the canalis sinuosus in 100 cone beam computed tomography
1482 examinations. *Oral Maxillofac Surg* 2015;19:49-53.
1483
- 1484 263. Fernández-Alonso A, Suárez-Quintanilla JA, Muínelo-Lorenzo J, Bornstein
1485 MM, Blanco-Carrión A, Suárez-Cunqueiro MM. Three-dimensional study of
1486 nasopalatine canal morphology: a descriptive retrospective analysis using cone-
1487 beam computed tomography. *Surg Radiol Anat* 2014;36:895-905.
1488
- 1489 264. Steier L, Steier G, Dođramaci EJ, Rossi-Fedele G. Maxillary sinus unilateral
1490 aplasia as an incidental finding following cone-beam computed (volumetric)
1491 tomography. *Aust Endod J* 2014;40:26-31.
1492
- 1493 265. Eshak M, Brooks S, Abdel-Wahed N, Edwards PC. Cone beam CT evaluation
1494 of the presence of anatomic accessory canals in the jaws. *Dentomaxillofac Radiol*
1495 2014;43:20130259.
1496

- 1497 266. Lea C, Deblinger J, Machado R, Nogueira Leal Silva EJ, Vansan LP. Maxillary
1498 premolar with 4 separate canals. *J Endod* 2014;40:591-593.
1499
- 1500 267. Sekerci AE, Buyuk SK, Cantekin K. Cone-beam computed tomographic
1501 analysis of the morphological characterization of the nasopalatine canal in a
1502 pediatric population. *Surg Radiol Anat* 2014;36:925-932.
1503
- 1504 268. İlgüy D, İlgüy M, Ersan N, Dölekoğlu S, Fişekçioğlu E. Measurements of the
1505 foramen magnum and mandible in relation to sex using CBCT. *J Forensic Sci*
1506 2014;59:601-605.
1507
- 1508 269. Filo K, Schneider T, Locher MC, Kruse AL, Lübbers HT. The inferior alveolar
1509 nerve's loop at the mental foramen and its implications for surgery. *J Am Dent*
1510 *Assoc* 2014;145:260-269.
1511
- 1512 270. Arslan H, Ertas ET, Topçuoğlu HS, Şekerci AE, Atici MY, Ertas H, Demirbuğa
1513 S. Radicular grooves of maxillary anterior teeth in a Turkish population: a cone-
1514 beam computed tomographic study. *Arch Oral Biol* 2014;59:297-301.
1515
- 1516 271. Kurt H, Orhan K, Aksoy S, Kursun S, Akbulut N, Bilecenoglu B. Evaluation of
1517 the superior semicircular canal morphology using cone beam computed tomography:
1518 a possible correlation for temporomandibular joint symptoms. *Oral Surg Oral Med*
1519 *Oral Pathol Oral Radiol* 2014;117:e280-288.
1520
- 1521 272. Jadhav AB, Fellows D, Hand AR, Tadinada A, Lurie AG. Classification and
1522 volumetric analysis of temporal bone pneumatization using cone beam computed
1523 tomography. *Oral Surg Oral Med Oral Pathol Oral Radiol* 2014;117:376-384.
1524
- 1525 273. Oztunç H, Evlice B, Tatli U, Evlice A. Cone-beam computed tomographic
1526 evaluation of styloid process: a retrospective study of 208 patients with orofacial
1527 pain. *Head Face Med* 2014;10:5.
1528
- 1529 274. Lin Z, Hu Q, Wang T, Ge J, Liu S, Zhu M, Wen S. Use of CBCT to investigate
1530 the root canal morphology of mandibular incisors. *Surg Radiol Anat* 2014;36:877-
1531 882.
1532
- 1533 275. Sekerci AE, Cantekin K, Aydinbelge M. Cone beam computed tomographic
1534 analysis of the shape, height, and location of the mandibular lingula in a population
1535 of children. *Biomed Res Int* 2013;2013:825453.
1536
- 1537 276. Etoz M, Sisman Y. Evaluation of the nasopalatine canal and variations with
1538 cone-beam computed tomography. *Surg Radiol Anat* 2014;36:805-812.
1539
- 1540 277. Sahman H, Sekerci AE, Ertas ET. Lateral lingual vascular canals of the

- 1541 mandible: a CBCT study of 500 cases. *Surg Radiol Anat* 2014;36:865-870.
1542
- 1543 278. Badole GP, Warhadpande MM, Sheno PR, Lachure C, Badole SG. A rare root
1544 canal configuration of bilateral maxillary first molar with 7 root canals diagnosed
1545 using cone-beam computed tomographic scanning: a case report. *J Endod*
1546 2014;40:296-301.
1547
- 1548 279. Silva EJ, Nejaim Y, Silva AI, Haiter-Neto F, Zaia AA, Cohenca N. Evaluation
1549 of root canal configuration of maxillary molars in a Brazilian population using cone-
1550 beam computed tomographic imaging: an in vivo study. *J Endod* 2014;40:173-176.
1551
- 1552 280. Mossaz J, Kloukos D, Pandis N, Suter VG, Katsaros C, Bornstein MM.
1553 Morphologic characteristics, location, and associated complications of maxillary and
1554 mandibular supernumerary teeth as evaluated using cone beam computed
1555 tomography. *Eur J Orthod* 2014;36:708-718.
1556
- 1557 281. Cantín M, Fonseca GM. Dens invaginatus in an impacted mesiodens: a
1558 morphological study. *Rom J Morphol Embryol* 2013;54(3 Suppl):879-884.
1559
- 1560 282. Perlea P, Nistor CC, Toma C, Dimitriu B. Endodontic configuration of the
1561 lower incisors in a Romanian population: a radiological study. *Rom J Morphol*
1562 *Embryol* 2013;54(3 Suppl):775-778.
1563
- 1564 283. Gaur A, Trivedi HP, Gupta M, Sharma A, Likhyani L, Agarwal M. Mandibular
1565 first molar with Vertucci type I canal configuration diagnosed with the help of cone
1566 beam computed tomography: a rare case report. *J Contemp Dent Pract* 2014;15:784-
1567 787.
1568
- 1569 284. Correr GM, Iwanko D, Leonardi DP, Ulbrich LM, Araújo MR, Deliberador
1570 TM. Classification of bifid mandibular canals using cone beam computed
1571 tomography. *Braz Oral Res* 2013;27:510-516.
1572
- 1573 285. Leite GM, Lana JP, de Carvalho Machado V, Manzi FR, Souza PE, Horta MC.
1574 Anatomic variations and lesions of the mandibular canal detected by cone beam
1575 computed tomography. *Surg Radiol Anat* 2014;36:795-804.
1576
- 1577 286. Paes da Silva Ramos Fernandes LM, Rice D, Ordinola-Zapata R, Alvares
1578 Capellozza AL, Bramante CM, Jaramillo D, Christensen H. Detection of various
1579 anatomic patterns of root canals in mandibular incisors using digital periapical
1580 radiography, 3 cone-beam computed tomographic scanners, and micro-computed
1581 tomographic imaging. *J Endod* 2014;40:42-45.
1582
- 1583 287. von Arx T, Friedli M, Sendi P, Lozanoff S, Bornstein MM. Location and

- 1584 dimensions of the mental foramen: a radiographic analysis by using cone-beam
1585 computed tomography. *J Endod* 2013;39:1522-1528.
1586
- 1587 288. Kim SY, Kim BS, Woo J, Kim Y. Morphology of mandibular first molars
1588 analyzed by cone-beam computed tomography in a Korean population: variations in
1589 the number of roots and canals. *J Endod* 2013;39:1516-1521.
1590
- 1591 289. Delilbasi C, Orhan K, Icen M, Aksoy S, Horasan S, Kenan Kose S. Evaluation
1592 of articular eminence pneumatization using cone beam computed tomography.
1593 *Minerva Stomatol* 2013;62:349-354.
1594
- 1595 290. Ilgüy D, Ilgüy M, Dolekoglu S, Fisekcioglu E. Evaluation of the posterior
1596 superior alveolar artery and the maxillary sinus with CBCT. *Braz Oral Res*
1597 2013;27:431-437.
1598
- 1599 291. Shin Y, Kim Y, Roh BD. Maxillary first molar with an O-shaped root
1600 morphology: report of a case. *Int J Oral Sci* 2013;5:242-244.
1601
- 1602 292. Mathew R, Omami G, Hand A, Fellows D, Lurie A. Cone beam CT analysis of
1603 Haller cells: prevalence and clinical significance. *Dentomaxillofac Radiol*
1604 2013;42:20130055.
1605
- 1606 293. Yang R, Yang C, Liu Y, Hu Y, Zou J. Evaluate root and canal morphology of
1607 primary mandibular second molars in Chinese individuals by using cone-beam
1608 computed tomography. *J Formos Med Assoc* 2013;112:390-395.
1609
- 1610 294. Kato H. Non-surgical endodontic treatment for dens invaginatus type III using
1611 cone beam computed tomography and dental operating microscope: a case report.
1612 *Bull Tokyo Dent Coll* 2013;54:103-108.
1613
- 1614 295. Orhan AI, Orhan K, Aksoy S, Ozgöl O, Horasan S, Arslan A, Kocyigit D.
1615 Evaluation of perimandibular neurovascularization with accessory mental foramina
1616 using cone-beam computed tomography in children. *J Craniofac Surg* 2013;24:e365-
1617 369.
1618
- 1619 296. Ikuta CR, Cardoso CL, Ferreira-Júnior O, Lauris JR, Souza PH, Rubira-Bullen
1620 IR. Position of the greater palatine foramen: an anatomical study through cone beam
1621 computed tomography images. *Surg Radiol Anat* 2013;35:837-842.
1622
- 1623 297. Silva EJ, Nejaim Y, Silva AV, Haiter-Neto F, Cohenca N. Evaluation of root
1624 canal configuration of mandibular molars in a Brazilian population by using cone-
1625 beam computed tomography: an in vivo study. *J Endod* 2013;39:849-852.
1626

- 1627 298. de Souza Tolentino E, Silva PA, Pagin O, Centurion BS, Molin SK, de Souza
1628 Tolentino L. Uncommon trajectory variations of the mandibular canal and of the
1629 mandibular incisive canal: case report. *Surg Radiol Anat* 2013;35:857-861.
1630
- 1631 299. Oetlé AC, Fourie J, Human-Baron R, van Zyl AW. The midline mandibular
1632 lingual canal: importance in implant surgery. *Clin Implant Dent Relat Res*
1633 2015;17:93-101.
1634
- 1635 300. Reis AG, Grazziotin-Soares R, Barletta FB, Fontanella VR, Mahl CR. Second
1636 canal in mesiobuccal root of maxillary molars is correlated with root third and
1637 patient age: a cone-beam computed tomographic study. *J Endod* 2013;39:588-592.
1638
- 1639 301. von Arx T, Lozanoff S, Sendi P, Bornstein MM. Assessment of bone channels
1640 other than the nasopalatine canal in the anterior maxilla using limited cone beam
1641 computed tomography. *Surg Radiol Anat* 2013;35:783-790.
1642
- 1643 302. Drage N, Rogers S, Greenall C, Playle R. Incidental findings on cone beam
1644 computed tomography in orthodontic patients. *J Orthod* 2013;40:29-37.
1645
- 1646 303. Demirbuga S, Sekerci AE, Dinçer AN, Cayabatmaz M, Zorba YO. Use of
1647 cone-beam computed tomography to evaluate root and canal morphology of
1648 mandibular first and second molars in Turkish individuals. *Med Oral Patol Oral Cir*
1649 *Bucal* 2013;18:e737-744.
1650
- 1651 304. Sonnesen L, Jensen KE, Petersson AR, Petri N, Berg S, Svanholt P. Cervical
1652 vertebral column morphology in patients with obstructive sleep apnoea assessed
1653 using lateral cephalograms and cone beam CT. A comparative study.
1654 *Dentomaxillofac Radiol* 2013;42:20130060.
1655
- 1656 305. Xu GZ, Yang C, Fan XD, Yu CQ, Cai XY, Wang Y, He D. Anatomic
1657 relationship between impacted third mandibular molar and the mandibular canal as
1658 the risk factor of inferior alveolar nerve injury. *Br J Oral Maxillofac Surg*
1659 2013;51:e215-219.
1660
- 1661 306. Patcas R, Tausch D, Pandis N, Manestar M, Ullrich O, Karlo CA, Peltomäki T,
1662 Kellenberger CJ. Illusions of fusions: assessing cervical vertebral fusion on lateral
1663 cephalograms, multidetector computed tomographs, and cone-beam computed
1664 tomographs. *Am J Orthod Dentofacial Orthop* 2013;143:213-220.
1665
- 1666 307. Anatomical differences in lower third molars visualized by 2D and 3D X-ray
1667 imaging: clinical outcomes after extraction. Jun SH, Kim CH, Ahn JS, Padwa BL,
1668 Kwon JJ. *Int J Oral Maxillofac Surg* 2013;42:489-496.
1669

- 1670 308. Han M, Wang RY, Liu H, Zhu XJ, Wei FL, Lv T, Wang NN, Hu LH, Li GJ,
1671 Liu DX, Wang CL. Association between mandibular posterior alveolar morphology
1672 and growth pattern in a Chinese population with normal occlusion. *J Zhejiang Univ*
1673 *Sci B* 2013;14:25-32.
- 1674
1675 309. Ladeira DB, Barbosa GL, Nascimento MC, Cruz AD, Freitas DQ, Almeida
1676 SM. Prevalence and characteristics of pneumatization of the temporal bone
1677 evaluated by cone beam computed tomography. *Int J Oral Maxillofac Surg*
1678 2013;42:771-775.
- 1679
1680 310. Sharma A, Sood PB, Singh A, Sachdeva S. Management of a rare case of
1681 impacted primary central incisors in a 3-year-old child. *J Indian Soc Pedod Prev*
1682 *Dent* 2012;30:271-274.
- 1683
1684 311. Liang RZ, Wu JT, Wu YN, Smales RJ, Hu M, Yu JH, Zhang GD. Bilateral
1685 maxillary fused second and third molars: a rare occurrence. *Int J Oral Sci*
1686 2012;4:231-234.
- 1687
1688 312. Imada TS, Fernandes LM, Centurion BS, de Oliveira-Santos C, Honório HM,
1689 Rubira-Bullen IR. Accessory mental foramina: prevalence, position and diameter
1690 assessed by cone-beam computed tomography and digital panoramic radiographs.
1691 *Clin Oral Implants Res* 2014;25:e94-99.
- 1692
1693 313. Han X, Yang H, Li G, Yang L, Tian C, Wang Y. A study of the distobuccal
1694 root canal orifice of the maxillary second molars in Chinese individuals evaluated by
1695 cone-beam computed tomography. *J Appl Oral Sci* 2012;20:563-567.
- 1696
1697 314. Kfir A, Telishevsky-Strauss Y, Leitner A, Metzger Z. The diagnosis and
1698 conservative treatment of a complex type 3 dens invaginatus using cone beam
1699 computed tomography (CBCT) and 3D plastic models. *Int Endod J* 2013;46:275-
1700 288.
- 1701
1702 315. Bernades-Mayordomo R, Guijarro-Martínez R, Hernández-Alfaro F.
1703 Volumetric CBCT analysis of the palatine process of the anterior maxilla: a potential
1704 source for bone grafts. *Int J Oral Maxillofac Surg* 2013;42:406-410.
- 1705
1706 316. Marca C, Dummer PM, Bryant S, Vier-Pelisser FV, Só MV, Fontanella V,
1707 Dutra VD, de Figueiredo JA. Three-rooted premolar analyzed by high-resolution
1708 and cone beam CT. *Clin Oral Investig* 2013;17:1535-1540.
- 1709
1710 317. Rege IC, Sousa TO, Leles CR, Mendonça EF. Occurrence of maxillary sinus
1711 abnormalities detected by cone beam CT in asymptomatic patients. *BMC Oral*
1712 *Health* 2012;12:30.
- 1713

- 1714 318. Orhan K, Kusakci Seker B, Aksoy S, Bayindir H, Berberoğlu A, Seker E. Cone
1715 beam CT evaluation of maxillary sinus septa prevalence, height, location and
1716 morphology in children and an adult population. *Med Princ Pract* 2013;22:47-53.
1717
- 1718 319. Baratto-Filho F, Leonardi DP, Crozeta BM, Baratto SP, Campos EA,
1719 Tomazinho FS, Deliberador TM. The challenges of treating a fused tooth. *Braz Dent*
1720 *J* 2012;23:256-262.
1721
- 1722 320. Castro IO, Alencar AH, Valladares-Neto J, Estrela C. Apical root resorption
1723 due to orthodontic treatment detected by cone beam computed tomography. *Angle*
1724 *Orthod* 2013;83:196-203.
1725
- 1726 321. Lizio G, Pelliccioni GA, Ghigi G, Fanelli A, Marchetti C. Radiographic
1727 assessment of the mandibular retromolar canal using cone-beam computed
1728 tomography. *Acta Odontol Scand* 2013;71:650-655.
1729
- 1730 322. Narayana P, Hartwell GR, Wallace R, Nair UP. Endodontic clinical
1731 management of a dens invaginatus case by using a unique treatment approach: a
1732 case report. *J Endod* 2012;38:1145-1148.
1733
- 1734 323. Kim Y, Lee SJ, Woo J. Morphology of maxillary first and second molars
1735 analyzed by cone-beam computed tomography in a korean population: variations in
1736 the number of roots and canals and the incidence of fusion. *J Endod* 2012;38:1063-
1737 1068.
1738
- 1739 324. Abella F, Patel S, Durán-Sindreu F, Mercadé M, Roig M. Mandibular first
1740 molars with disto-lingual roots: review and clinical management. *Int Endod J*
1741 2012;45:963-978.
1742
- 1743 325. Chen JC, Lin LM, Geist JR, Chen JY, Chen CH, Chen YK. A retrospective
1744 comparison of the location and diameter of the inferior alveolar canal at the mental
1745 foramen and length of the anterior loop between American and Taiwanese cohorts
1746 using CBCT. *Surg Radiol Anat* 2013;35:11-18.
1747
- 1748 326. de Oliveira-Santos C, Rubira-Bullen IR, Monteiro SA, León JE, Jacobs R.
1749 Neurovascular anatomical variations in the anterior palate observed on CBCT
1750 images. *Clin Oral Implants Res* 2013;24:1044-1048.
1751
- 1752 327. Tian YY, Guo B, Zhang R, Yu X, Wang H, Hu T, Dummer PM. Root and
1753 canal morphology of maxillary first premolars in a Chinese subpopulation evaluated
1754 using cone-beam computed tomography. *Int Endod J* 2012;45:996-1003.
1755
- 1756 328. Tozoglu U, Caglayan F, Harorli A. Foramen tympanicum or foramen of
1757 Huschke: anatomical cone beam CT study. *Dentomaxillofac Radiol* 2012;41:294-
1758 297.

- 1759
1760 329. Güldner C, Zimmermann AP, Diogo I, Werner JA, Teymoortash A. Age-
1761 dependent differences of the anterior skull base. *Int J Pediatr Otorhinolaryngol*
1762 2012;76:822-828.
- 1763
1764 330. Seo DG, Gu Y, Yi YA, Lee SJ, Jeong JS, Lee Y, Chang SW, Lee JK, Park W,
1765 Kim KD, Kum KY. A biometric study of C-shaped root canal systems in mandibular
1766 second molars using cone-beam computed tomography. *Int Endod J* 2012;45:807-
1767 814.
- 1768
1769 331. Barghan S, Tetradis S, Mallya S. Application of cone beam computed
1770 tomography for assessment of the temporomandibular joints. *Aust Dent J* 2012;57
1771 Suppl 1:109-118.
- 1772
1773 332. Güldner C, Pistorius SM, Diogo I, Bien S, Sesterhenn A, Werner JA. Analysis
1774 of pneumatization and neurovascular structures of the sphenoid sinus using cone-
1775 beam tomography (CBT). *Acta Radiol* 2012;53:214-219.
- 1776
1777 333. Marquezan M, Nojima LI, Freitas AO, Baratieri C, Alves Júnior M, Nojima
1778 Mda C, Araújo MT. Tomographic mapping of the hard palate and overlying mucosa.
1779 *Braz Oral Res* 2012;26:36-42.
- 1780
1781 334. Neves FS, Crusoé-Souza M, Franco LC, Caria PH, Bonfim-Almeida P, Crusoé-
1782 Rebello I. Canalis sinuosus: a rare anatomical variation. *Surg Radiol Anat*
1783 2012;34:563-566.
- 1784
1785 335. von Arx T, Hänni A, Sendi P, Buser D, Bornstein MM. Radiographic study of
1786 the mandibular retromolar canal: an anatomic structure with clinical importance. *J*
1787 *Endod* 2011;37:1630-1635.
- 1788
1789 336. Rosano G, Gaudy JF, Chaumanet G, Del Fabbro M, Taschieri S. [Maxillary
1790 sinus septa. Prevalence and anatomy]. *Rev Stomatol Chir Maxillofac* 2012;113:32-
1791 35.
- 1792
1793 337. Vier-Pelisser FV, Pelisser A, Recuero LC, Só MV, Borba MG, Figueiredo JA.
1794 Use of cone beam computed tomography in the diagnosis, planning and follow up of
1795 a type III dens invaginatus case. *Int Endod J* 2012;45:198-208.
- 1796
1797 338. Babiuc I, Tărlungeanu I, Păuna M. Cone beam computed tomography
1798 observations of the lingual foramina and their bony canals in the median region of
1799 the mandible. *Rom J Morphol Embryol* 2011;52:827-829.
- 1800
1801 339. Kaneko T, Sakaue H, Okiji T, Suda H. Clinical management of dens
1802 invaginatus in a maxillary lateral incisor with the aid of cone-beam computed
1803 tomography--a case report. *Dent Traumatol* 2011;27:478-483.

1804
1805
1806
1807
1808
1809
1810
1811
1812
1813
1814
1815
1816
1817
1818
1819
1820
1821
1822
1823
1824
1825
1826
1827
1828
1829
1830
1831
1832
1833
1834
1835
1836
1837
1838
1839
1840
1841
1842
1843
1844
1845
1846
1847
1848

340. Uysal T, Yagci A, Ucar FI, Veli I, Ozer T. Cone-beam computed tomography evaluation of relationship between tongue volume and lower incisor irregularity. *Eur J Orthod* 2013;35:555-562.

341. Mizbah K, Gerlach N, Maal TJ, Bergé SJ, Meijer GJ. The clinical relevance of bifid and trifid mandibular canals. *Oral Maxillofac Surg* 2012;16:147-151.

342. Abella F, Mercadé M, Duran-Sindreu F, Roig M. Managing severe curvature of radix entomolaris: three-dimensional analysis with cone beam computed tomography. *Int Endod J* 2011;44:876-885.

343. Zhang R, Wang H, Tian YY, Yu X, Hu T, Dummer PM. Use of cone-beam computed tomography to evaluate root and canal morphology of mandibular molars in Chinese individuals. *Int Endod J* 2011;44:990-999.

344. Oliveira-Santos C, Capelozza AL, Dezzoti MS, Fischer CM, Poleti ML, Rubira-Bullen IR. Visibility of the mandibular canal on CBCT cross-sectional images. *J Appl Oral Sci* 2011;19:240-243.

345. Orhan K, Sakul BU, Oz U, Bilecenoglu B. Evaluation of the pterygoid hamulus morphology using cone beam computed tomography. *Oral Surg Oral Med Oral Pathol Oral Radiol Endod* 2011;112:e48-55.

346. Zheng Q, Zhang L, Zhou X, Wang Q, Wang Y, Tang L, Song F, Huang D. C-shaped root canal system in mandibular second molars in a Chinese population evaluated by cone-beam computed tomography. *Int Endod J* 2011;44:857-862.

347. Swasty D, Lee J, Huang JC, Maki K, Gansky SA, Hatcher D, Miller AJ. Cross-sectional human mandibular morphology as assessed in vivo by cone-beam computed tomography in patients with different vertical facial dimensions. *Am J Orthod Dentofacial Orthop* 2011;139:e377-389.

348. Kottoor J, Velmurugan N, Ballal S, Roy A. Four-rooted maxillary first molar having C-shaped palatal root canal morphology evaluated using cone-beam computerized tomography: a case report. *Oral Surg Oral Med Oral Pathol Oral Radiol Endod* 2011;111:e41-45.

349. Lee JH, Kim KD, Lee JK, Park W, Jeong JS, Lee Y, Gu Y, Chang SW, Son WJ, Lee WC, Baek SH, Bae KS, Kum KY. Mesio Buccal root canal anatomy of Korean maxillary first and second molars by cone-beam computed tomography. *Oral Surg Oral Med Oral Pathol Oral Radiol Endod* 2011;111:785-791.

350. Suter VG, Sendi P, Reichart PA, Bornstein MM. The nasopalatine duct cyst: an analysis of the relation between clinical symptoms, cyst dimensions, and

- 1849 involvement of neighboring anatomical structures using cone beam computed
1850 tomography. *J Oral Maxillofac Surg* 2011;69:2595-2603.
- 1851
- 1852 351. da Silva Ramos Fernandes LM, Capelozza AL, Rubira-Bullen IR. Absence and
1853 hypoplasia of the mental foramen detected in CBCT images: a case report. *Surg*
1854 *Radiol Anat* 2011;33:731-734.
- 1855
- 1856 352. Kim SY, Choi SC, Chung YJ. Management of the fused permanent upper
1857 lateral incisor: a case report. *Oral Surg Oral Med Oral Pathol Oral Radiol Endod*
1858 2011;111:649-652.
- 1859
- 1860 353. Kovisto T, Ahmad M, Bowles WR. Proximity of the mandibular canal to the
1861 tooth apex. *J Endod* 2011;37:311-315.
- 1862
- 1863 354. Durack C, Patel S. The use of cone beam computed tomography in the
1864 management of dens invaginatus affecting a strategic tooth in a patient affected by
1865 hypodontia: a case report. *Int Endod J* 2011;44:474-483.
- 1866
- 1867 355. Yamada T, Ishihama K, Yasuda K, Hasumi-Nakayama Y, Ito K, Yamaoka M,
1868 Furusawa K. Inferior alveolar nerve canal and branches detected with dental cone
1869 beam computed tomography in lower third molar region. *J Oral Maxillofac Surg*
1870 2011;69:1278-1282.
- 1871
- 1872 356. Bebnowski D, Hänggi MP, Markic G, Roos M, Peltomäki T. Cervical vertebrae
1873 anomalies in subjects with Class II malocclusion assessed by lateral cephalogram
1874 and cone beam computed tomography. *Eur J Orthod* 2012;34:226-231.
- 1875
- 1876 357. Rogers SA, Drage N, Durning P. Incidental findings arising with cone beam
1877 computed tomography imaging of the orthodontic patient. *Angle Orthod*
1878 2011;81:350-355.
- 1879
- 1880 358. Orhan K, Aksoy S, Bilecenoglu B, Sakul BU, Paksoy CS. Evaluation of bifid
1881 mandibular canals with cone-beam computed tomography in a Turkish adult
1882 population: a retrospective study. *Surg Radiol Anat* 2011;33:501-507.
- 1883
- 1884 359. Oliveira-Santos C, Souza PH, De Azambuja Berti-Couto S, Stinkens L,
1885 Moyaert K, Van Assche N, Jacobs R. Characterisation of additional mental foramina
1886 through cone beam computed tomography. *J Oral Rehabil* 2011;38:595-600.
- 1887
- 1888 360. Zhang R, Yang H, Yu X, Wang H, Hu T, Dummer PM. Use of CBCT to
1889 identify the morphology of maxillary permanent molar teeth in a Chinese
1890 subpopulation. *Int Endod J* 2011;44:162-169.
- 1891
- 1892 361. Chan HL, Brooks SL, Fu JH, Yeh CY, Rudek I, Wang HL. Cross-sectional
1893 analysis of the mandibular lingual concavity using cone beam computed

- 1894 tomography. Clin Oral Implants Res 2011;22:201-206.
1895
- 1896 362. Bornstein MM, Balsiger R, Sendi P, von Arx T. Morphology of the
1897 nasopalatine canal and dental implant surgery: a radiographic analysis of 100
1898 consecutive patients using limited cone-beam computed tomography. Clin Oral
1899 Implants Res 2011;22:295-301.
1900
- 1901 363. Krithikadatta J, Kottoor J, Karumaran CS, Rajan G. Mandibular first molar
1902 having an unusual mesial root canal morphology with contradictory cone-beam
1903 computed tomography findings: a case report. J Endod 2010;36:1712-1716.
1904
- 1905 364. Neelakantan P, Subbarao C, Ahuja R, Subbarao CV, Gutmann JL. Cone-beam
1906 computed tomography study of root and canal morphology of maxillary first and
1907 second molars in an Indian population. J Endod 2010;36:1622-1627.
1908
- 1909 365. Fuakami K, Shiozaki K, Mishima A, Shimoda S, Hamada Y, Kobayashi K.
1910 Detection of buccal perimandibular neurovascularisation associated with accessory
1911 foramina using limited cone-beam computed tomography and gross anatomy. Surg
1912 Radiol Anat 2011;33:141-146.
1913
- 1914 366. Yu Q, Pan XG, Ji GP, Shen G. The association between lower incisal
1915 inclination and morphology of the supporting alveolar bone--a cone-beam CT study.
1916 Int J Oral Sci 2009;1:217-223.
1917
- 1918 367. Angel JS, Mincer HH, Chaudhry J, Scarbecz M. Cone-beam computed
1919 tomography for analyzing variations in inferior alveolar canal location in adults in
1920 relation to age and sex. J Forensic Sci 2011;56:216-219.
1921
- 1922 368. Michetti J, Maret D, Mallet JP, Diemer F. Validation of cone beam computed
1923 tomography as a tool to explore root canal anatomy. J Endod 2010;36:1187-1190.
1924
- 1925 369. Patel S. The use of cone beam computed tomography in the conservative
1926 management of dens invaginatus: a case report. Int Endod J 2010;43:707-713.
1927
- 1928 370. Huang CC, Chang YC, Chuang MC, Lai TM, Lai JY, Lee BS, Lin CP.
1929 Evaluation of root and canal systems of mandibular first molars in Taiwanese
1930 individuals using cone-beam computed tomography. J Formos Med Assoc
1931 2010;109:303-308.
1932
- 1933 371. Kottoor J, Velmurugan N, Sudha R, Hemamalathi S. Maxillary first molar with
1934 seven root canals diagnosed with cone-beam computed tomography scanning: a case
1935 report. J Endod 2010;36:915-921.
1936
- 1937 372. La SH, Jung DH, Kim EC, Min KS. Identification of independent middle

- 1938 mesial canal in mandibular first molar using cone-beam computed tomography
1939 imaging. *J Endod* 2010;36:542-545.
1940
- 1941 373. Deguchi T Sr, Katashiba S, Inami T, Foong KW, Huak CY. Morphologic
1942 quantification of the maxilla and the mandible with cone-beam computed
1943 tomography. *Am J Orthod Dentofacial Orthop* 2010;137:218-222.
1944
- 1945 374. Kottoor J, Hemamalathi S, Sudha R, Velmurugan N. Maxillary second molar
1946 with 5 roots and 5 canals evaluated using cone beam computerized tomography: a
1947 case report. *Oral Surg Oral Med Oral Pathol Oral Radiol Endod* 2010;109:e162-165.
1948
- 1949 375. Bornstein MM, Wiest R, Balsiger R, Reichart PA. Anterior Stafne's bone cavity
1950 mimicking a periapical lesion of endodontic origin: report of two cases. *J Endod*
1951 2009;35:1598-1602.
1952
- 1953 376. Pires CA, Bissada NF, Becker JJ, Kanawati A, Landers MA. Clin Implant
1954 Mandibular incisive canal: cone beam computed tomography. *Dent Relat Res*
1955 2012;14:67-73.
1956
- 1957 377. Naitoh M, Nakahara K, Hiraiwa Y, Aimiya H, Gotoh K, Arijji E. Observation
1958 of buccal foramen in mandibular body using cone-beam computed tomography.
1959 *Okajimas Folia Anat Jpn* 2009;86:25-29.
1960
- 1961 378. Tu MG, Huang HL, Hsue SS, Hsu JT, Chen SY, Jou MJ, Tsai CC. Detection of
1962 permanent three-rooted mandibular first molars by cone-beam computed
1963 tomography imaging in Taiwanese individuals. *J Endod* 2009;35:503-507.
1964
- 1965 379. Naitoh M, Hiraiwa Y, Aimiya H, Gotoh K, Arijji E. Accessory mental foramen
1966 assessment using cone-beam computed tomography. *Oral Surg Oral Med Oral*
1967 *Pathol Oral Radiol Endod* 2009;107:289-294.
1968
- 1969 380. Katakami K, Mishima A, Shiozaki K, Shimoda S, Hamada Y, Kobayashi
1970 K. Characteristics of accessory mental foramina observed on limited cone-beam
1971 computed tomography images. *J Endod* 2008;34:1441-1445.
1972
- 1973 381. Popat H, Drage N, Durning P. Mid-line clefts of the cervical vertebrae - an
1974 incidental finding arising from cone beam computed tomography of the dental
1975 patient. *Br Dent J* 2008;204:303-306.
1976
- 1977 382. Sato I, Arai H, Asaumi R, Imura K, Kawai T, Yosue T. Classifications of
1978 tunnel-like structure of human petrotympanic fissure by cone beam CT. *Surg Radiol*
1979 *Anat* 2008;30:323-326.
1980

- 1981 383. King KS, Lam EW, Faulkner MG, Heo G, Major PW. Vertical bone volume in
1982 the paramedian palate of adolescents: a computed tomography study. Am J Orthod
1983 Dentofacial Orthop 2007;132:783-788.
1984
- 1985 384. Rouas P, Nancy J, Bar D. Identification of double mandibular canals: literature
1986 review and three case reports with CT scans and cone beam CT. Dentomaxillofac
1987 Radiol 2007;36:34-38.
1988
- 1989 385. Liu DG, Zhang WL, Zhang ZY, Wu YT, Ma XC. Three-dimensional
1990 evaluations of supernumerary teeth using cone-beam computed tomography for 487
1991 cases. Oral Surg Oral Med Oral Pathol Oral Radiol Endod 2007;103:403-411.
1992